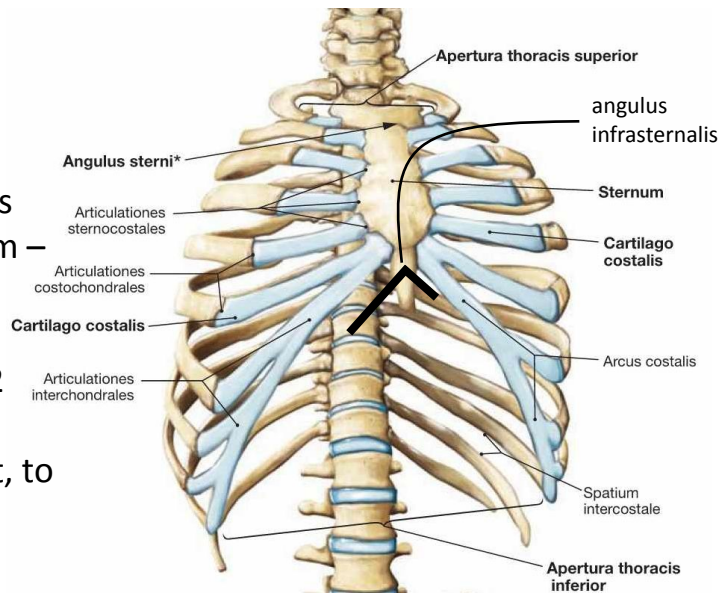
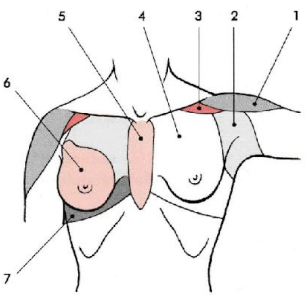
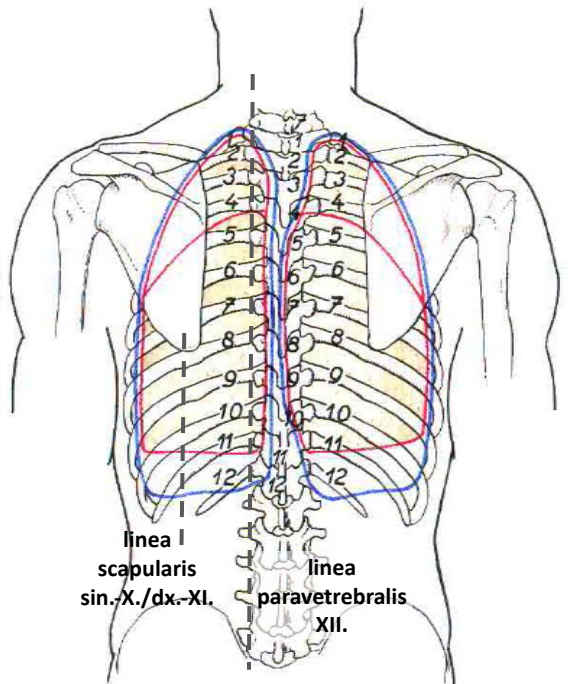
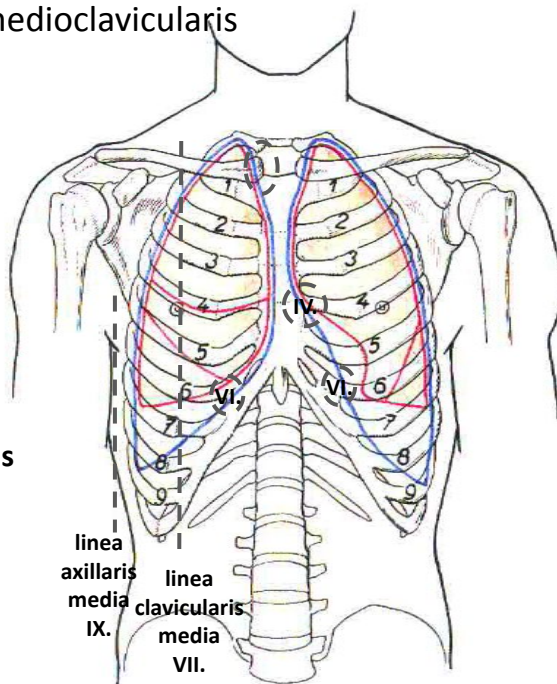


# CHEST REGIONS

- Bony framework: thoracic spine, ribs, sternum
- Upper border
  - Superficially: jugular fossa – clavicle – acromion – C7 spinous process
  - Deeply: superior thoracic aperture = upper margin of the manubrium – first rib – body of Th1
- lower border
  - superficially: xiphoid process – costal arch – spinous process of Th12
  - inferior thoracic aperture = costal arches – last ribs – body of Th12
  - deeply: diaphragm (projects to the 4th intercostal space on the right, to the 5th intercostal space on the left)
- palpable: costal cartilages, sternal margin, ribs (except the first)
- orientation and projection of organs using vertical lines:



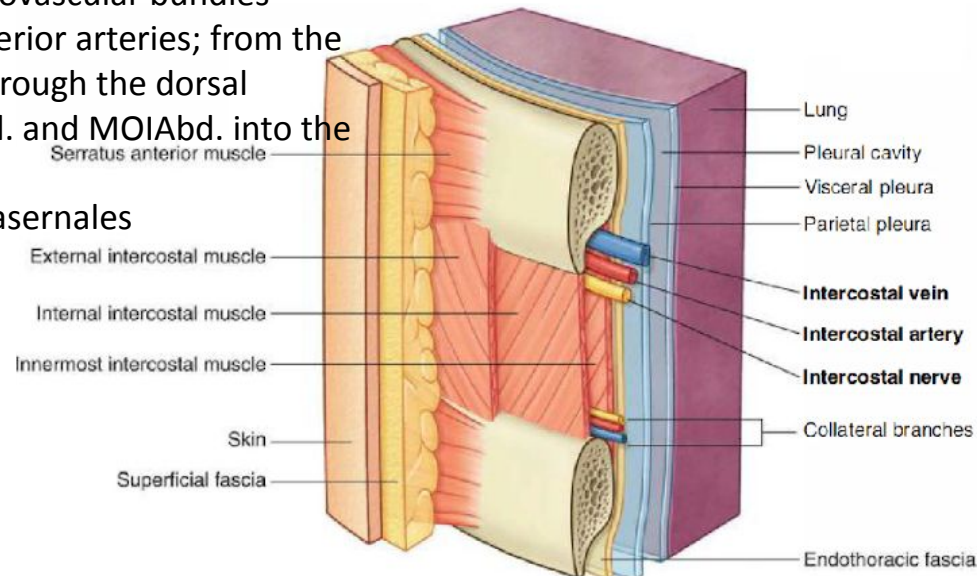
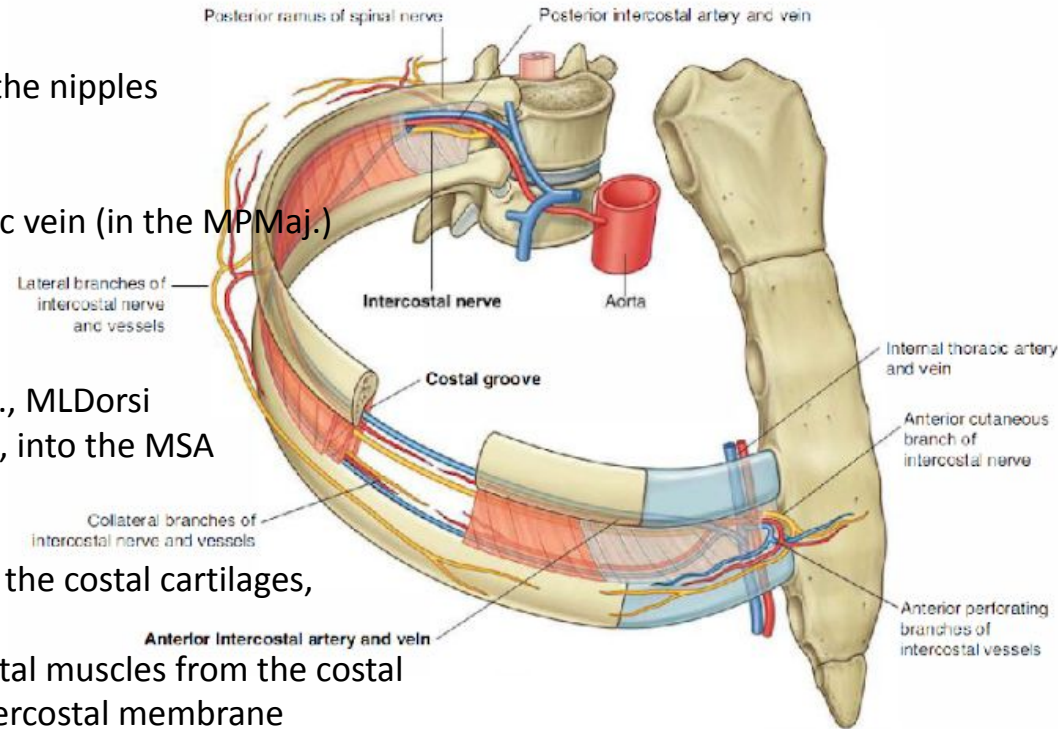
- mediana anterior – midline
- sternalis – sternal border
- parasternalis – between sternalis and medioclavicularis
- medioclavicularis
- axillaris anterior
- axillaris media
- axillaris posterior
- scapularis
- paravertebralis
- mediana posterior

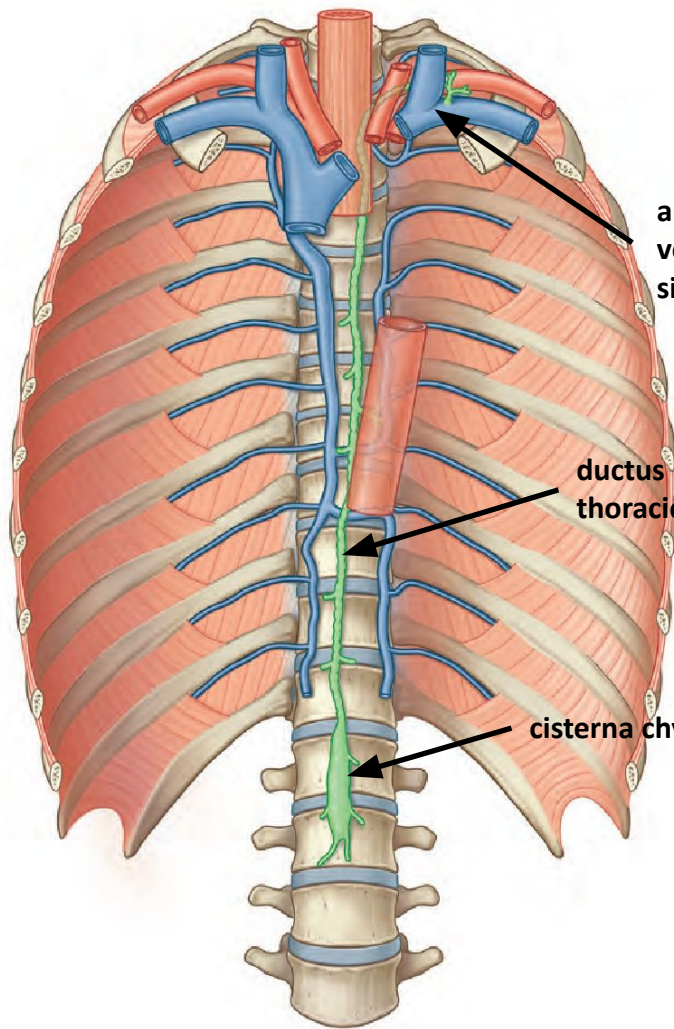


- 1 - regio deltoidea
- 2 - regio axillaris et fossa axillaris
- 3 - fossa infraclavicularis and trigonum clavipectorale
- 4 - regio pectoralis
- 5 - regio presternalis
- 6 - regio mammaria
- 7 - regio inframammaria

# TOPOGRAPHY OF THE THORACIC WALL

- skin
  - in men, hair in the sternal region and around the nipples
  - fat outside the area in front of the sternum
- subcutaneous tissue
  - thoracoepigastric veins into the lateral thoracic vein (in the MPMaj.)
  - lateral and anterior cutaneous branches
  - supraclavicular nerves
- the thoracic fascia covers:
  - the MPMaj. and Min. muscles, MSA, MOEAbd., MLDorsi
  - the long thoracic nerve in the mid-axillary line, into the MSA
  - lateral thoracic artery
- intercostal spaces
  - external intercostal muscles from the spine to the costal cartilages, ventrally the external intercostal membrane
  - internal intercostal muscles and deep intercostal muscles from the costal angle to the sternum, dorsally the internal intercostal membrane
  - between the interni and intimi run intercostal neurovascular bundles (anastomoses of branches of the anterior and posterior arteries; from the 7th intercostal space, the nn. intercostales enter through the dorsal surface of the costal cartilages between the MTAbd. and MOIAbd. into the abdominal wall)
  - lymph to the nodi lymphatici intercostales and parasernales
- endothoracic fascia on the inner surface of the chest

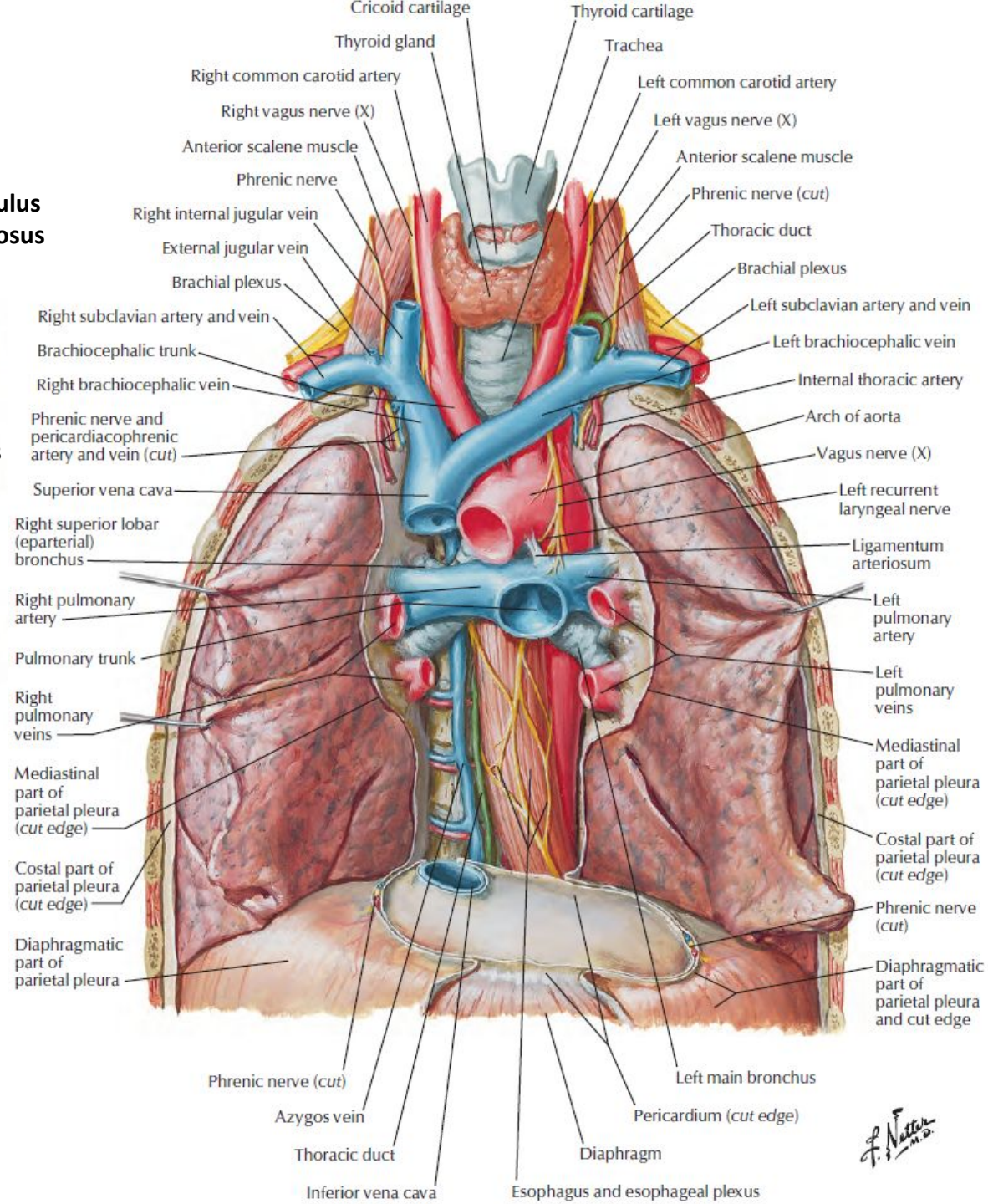




**angulus  
venosus  
sin.**

**ductus  
thoracicus**

**cisterna chyli**

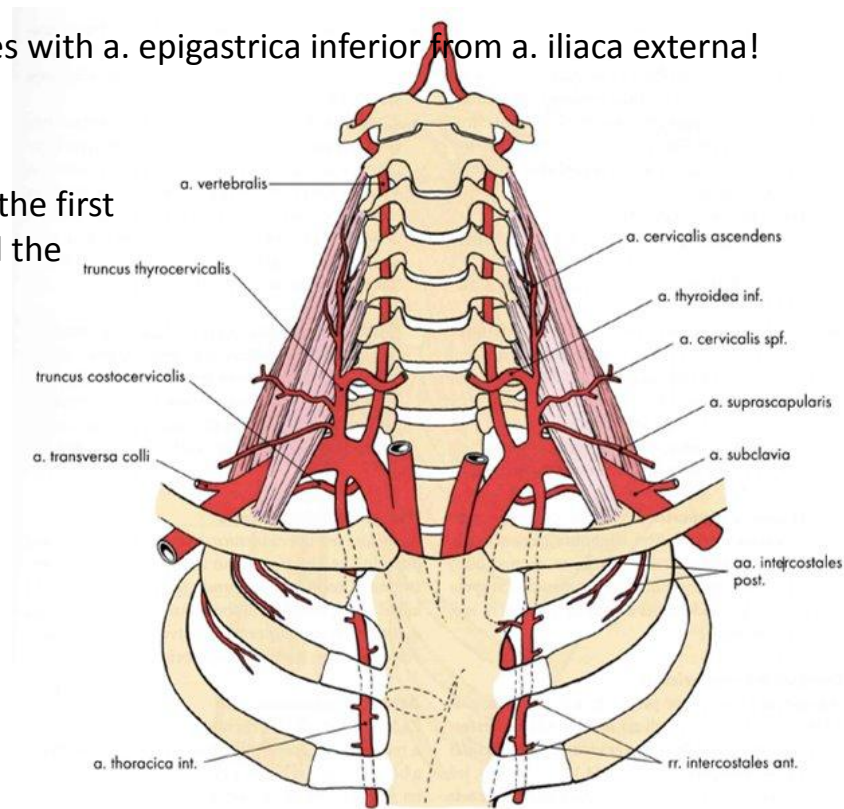


- Thyroid gland
- Trachea
- Right common carotid artery
- Left common carotid artery
- Right vagus nerve (X)
- Left vagus nerve (X)
- Anterior scalene muscle
- Phrenic nerve
- Phrenic nerve (cut)
- Right internal jugular vein
- External jugular vein
- Thoracic duct
- Brachial plexus
- Brachial plexus
- Right subclavian artery and vein
- Left subclavian artery and vein
- Brachiocephalic trunk
- Left brachiocephalic vein
- Right brachiocephalic vein
- Internal thoracic artery
- Phrenic nerve and pericardiophrenic artery and vein (cut)
- Arch of aorta
- Superior vena cava
- Vagus nerve (X)
- Right superior lobar (eparterial) bronchus
- Left recurrent laryngeal nerve
- Right pulmonary artery
- Ligamentum arteriosum
- Pulmonary trunk
- Left pulmonary artery
- Right pulmonary veins
- Left pulmonary veins
- Mediastinal part of parietal pleura (cut edge)
- Mediastinal part of parietal pleura (cut edge)
- Costal part of parietal pleura (cut edge)
- Costal part of parietal pleura (cut edge)
- Diaphragmatic part of parietal pleura
- Phrenic nerve (cut)
- Diaphragmatic part of parietal pleura and cut edge
- Phrenic nerve (cut)
- Azygos vein
- Thoracic duct
- Inferior vena cava
- Diaphragm
- Esophagus and esophageal plexus
- Left main bronchus
- Pericardium (cut edge)

*F. Netter M.D.*

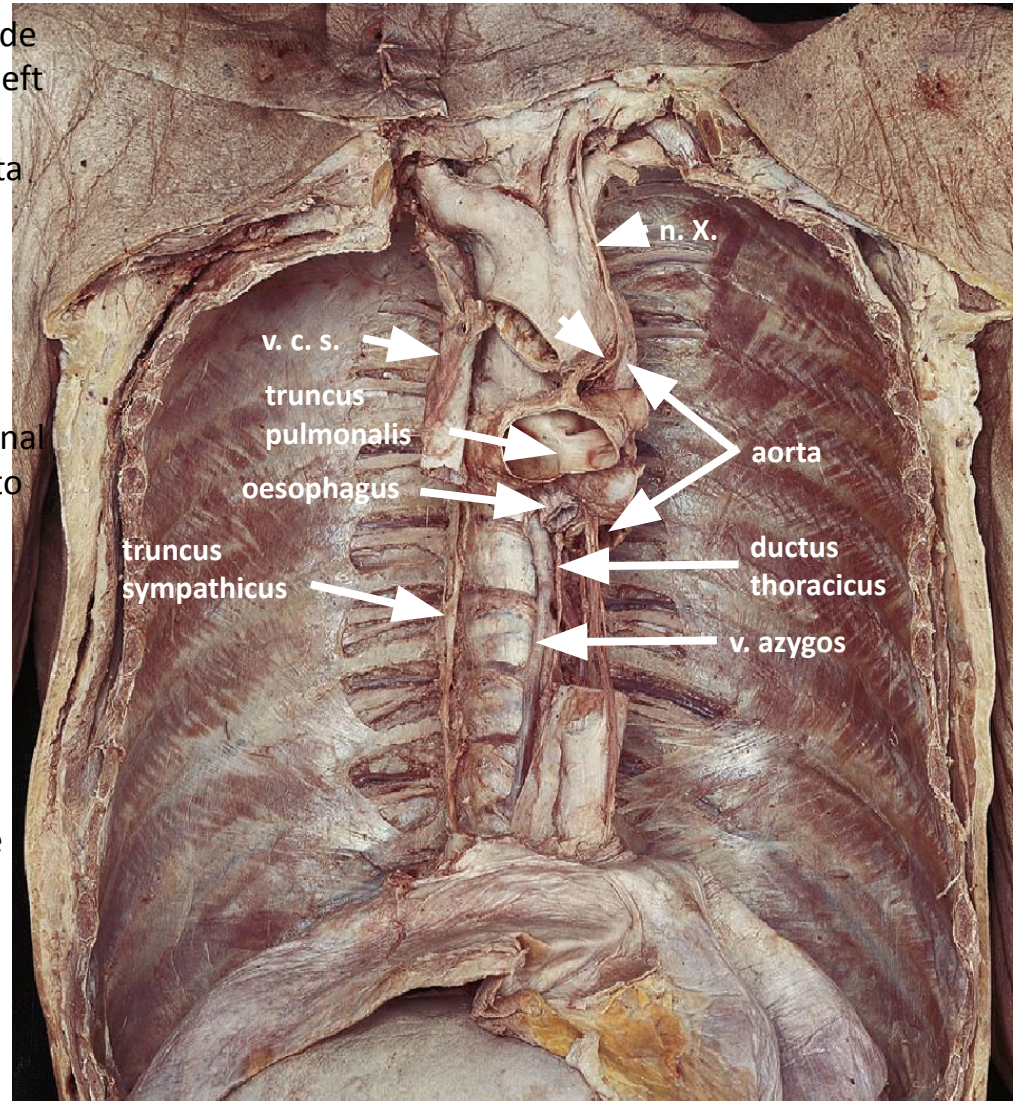
# BRANCHES OF THE SUBCLAVIAN ARTERY

- a. vertebralis
- internal thoracic artery
  - it branches off from the vertebral artery and descends through the anterior mediastinum behind the costal cartilages between the bundles of the transverse thoracic muscle about 1 cm from the edge of the sternum. at the level of the 6th rib, it divides into its terminal branches, the musculophrenic artery and the superior epigastric artery (passing through the sternocostal trigone of the diaphragm to the posterior surface of the rectus abdominis muscle, the internal thoracic artery is renamed the epigastric artery)
  - a. pericardiophrenica – pericardium and mediastinal pleura
  - rr. mediastinales – thymus, bronchi
  - rr. intercostales anteriores – two in each intercostal space to the upper and lower edges of the adjacent ribs; in the second to fifth intercostal spaces in women, they give rise to the rr. mammarii for the mammary gland and anastomose with the aa. intercostales posteriores
  - a. epigastrica superior – in m. rectus abdominis anastomoses with a. epigastrica inferior from a. iliaca externa!
- thyrocervical trunk
- costocervical trunk
  - departs from the pars interscalenica dorsally to the neck of the first rib and divides into the ascending a. cervicalis profunda and the descending a. intercostalis suprema
- transversus colli artery

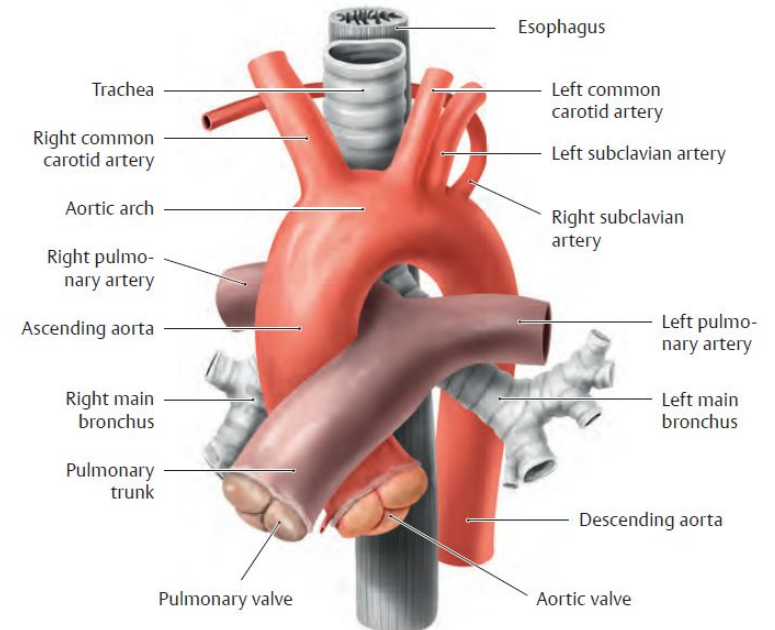
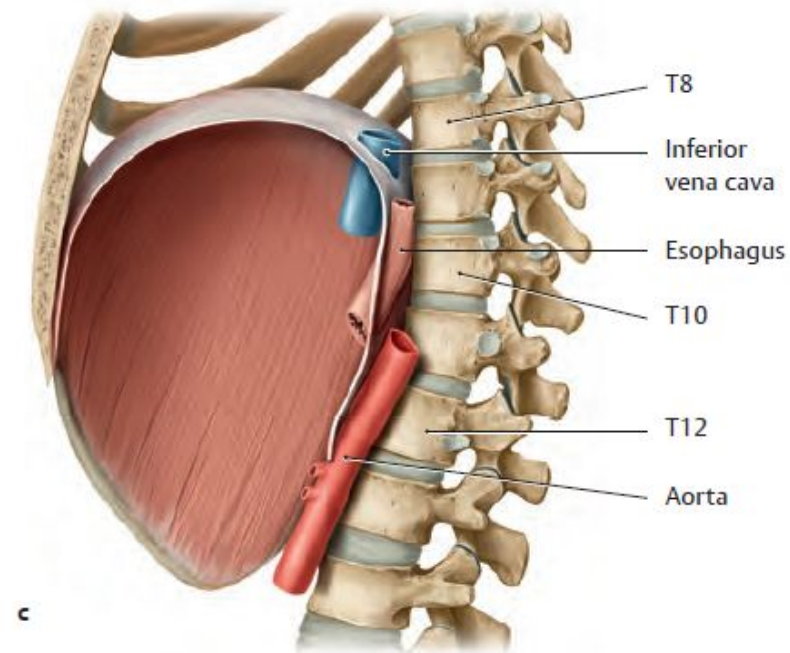
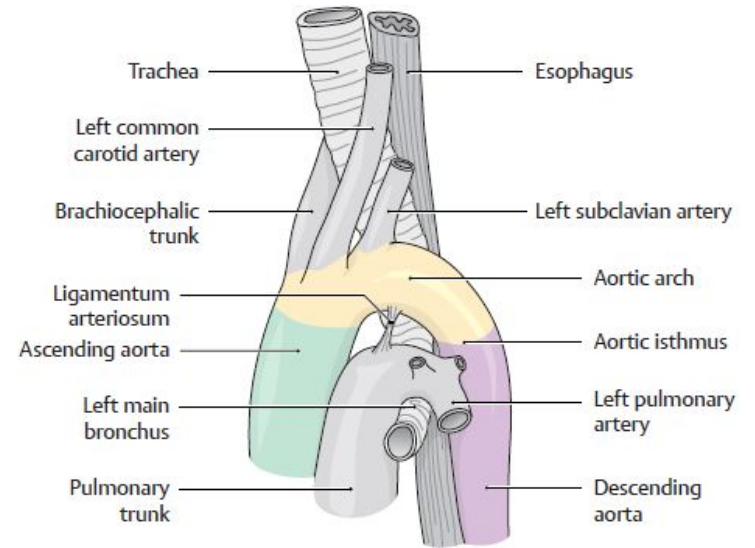
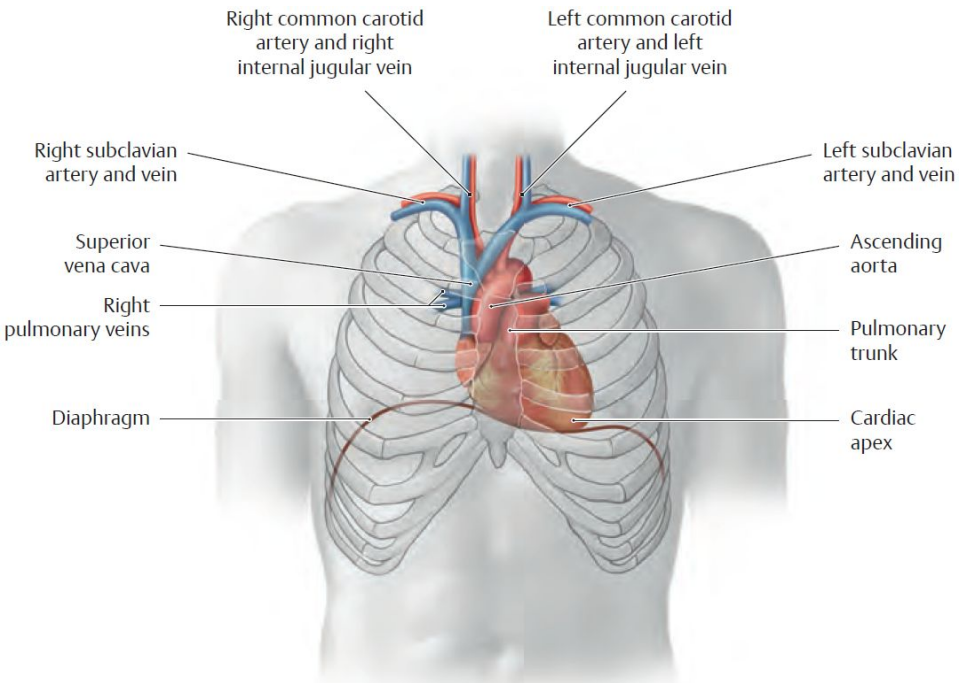


# THORACIC AORTA

- runs through the posterior mediastinum from the left side of Th3 to the aortic hiatus (Th11–12), passing from the left in front of the vertebral bodies
- esophagus first on the right, caudally in front of the aorta and to the left
- on the right: thoracic duct and v. azygos (more laterally)
- cranially in front of the aorta radix pulmonis sinistri, caudally heart in the pericardium
- left: v. hemiazygos
- from the sides, it presses on the thoracic aorta mediastinal pleura of both pleural cavities, the aorta is imprinted into the left lung through the mediastinal pleura
- visceral branches
  - rr. bronchiales
  - rr. oesophagei
  - rr. mediastinales
- parietal branches
  - a. phrenica superior
  - aa. intercostales posteriores – rr. dorsales (for the back muscles and skin), rr. spinales (for the spinal canal, spinal cord, and spinal membranes), rr. collaterales (to the upper edge of the next rib), rr. cutanei laterales (to the subcutaneous tissue, in women branches rr. mammarii laterales for the mammary gland)
  - a. subcostalis (a. intercostalis posterior below the 12th rib in the muscles of the abdominal wall)



# TOPOGRAPHICAL RELATIONS IN THE THORACIC CAVITY



# Thoracic veins

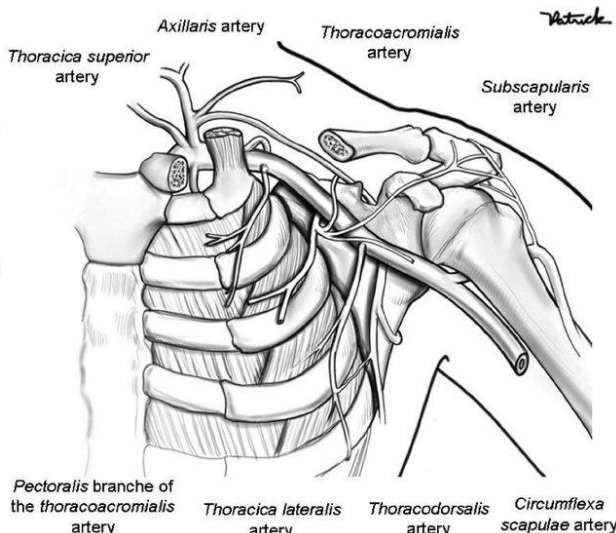
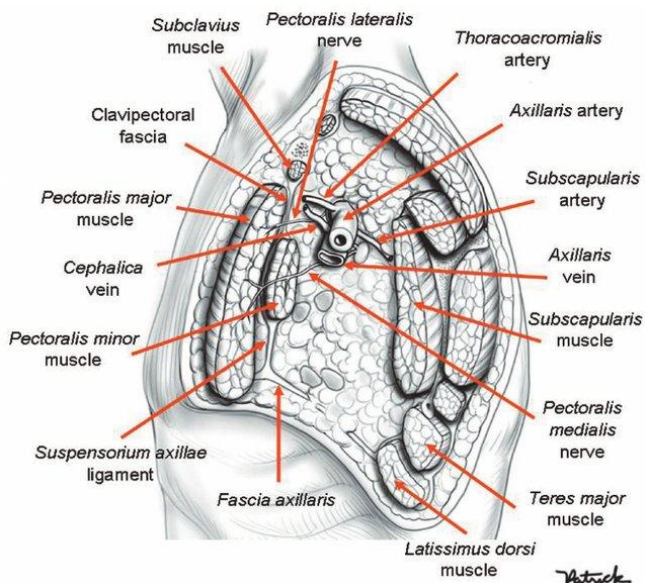
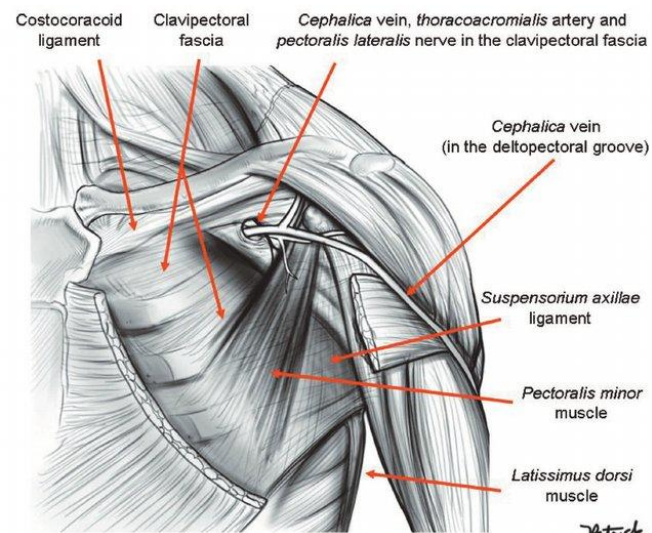
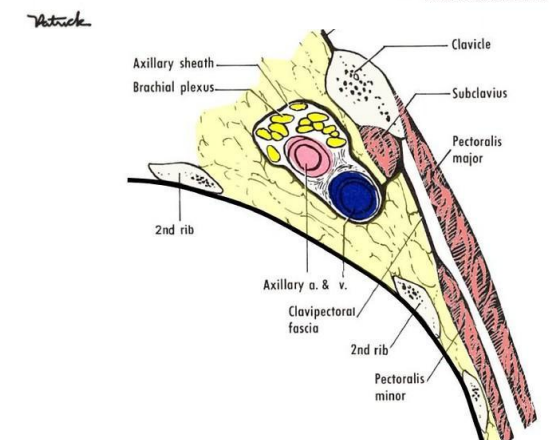
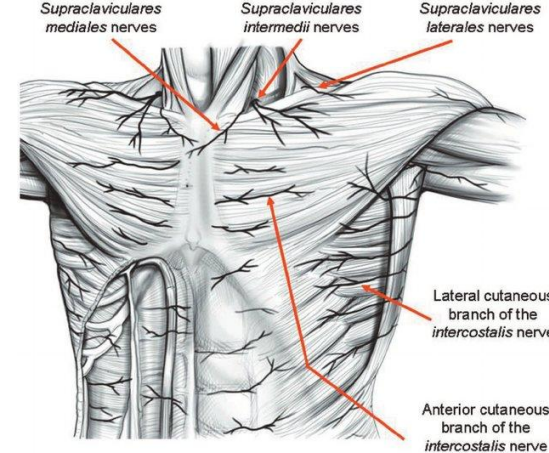
- azygos and hemiazygos running along the spine; their tributaries originate from the lumbar wall and, in the thorax, primarily from the area supplied by the thoracic aorta
- collect blood from the lumbar wall, from the 8–10 caudal intercostal spaces, from the organs of the posterior mediastinum, from the pulmonary venous circulation, and from the spinal venous plexuses
- have no valves (blood flows in both directions; part of the so-called cavocaval anastomoses)
- azygos vein
  - on the right, begins at the confluence of the right ascending lumbar vein and the right subcostal vein behind the cranial origins of the psoas major muscle below the diaphragm
  - passes through the diaphragm via the crus dextrum into the posterior mediastinum; at the level of T4, the arcus venae azygos joins the superior vena cava (above the pericardium); above the pulmonary hilum, it leaves the sulcus venae azygos
  - posterior intercostal veins, esophageal veins (in the lower part of the esophagus, the junction of the superior vena cava and portal vein), bronchial veins
- hemiazygos vein
  - on the left, extends to the level of T7–9; here, it passes obliquely between the spine and the aorta and empties into the azygos vein
  - posterior left intercostal veins from the lower 6 intercostal spaces, bronchial veins, esophageal veins
  - accessory hemiazygos vein – on the left, originates from branches of the superior intercostal vein, receives blood from the posterior left intercostal veins, opens into the oblique portion of the hemiazygos vein
- brachiocephalic vein
  - behind the sternoclavicular joint, at the junction of the internal jugular vein and the subclavian vein (venous angle)
  - by their union – superior vena cava
  - right: descends vertically (length 3 cm) behind the right margin of the manubrium
  - left: descends obliquely (length 6 cm), in front of the remnants of the thymus (corpus thymicum) and the thymus gland; behind are the arteries from the aortic arch
  - veins from the mediastinum – thymic, pericardial, bronchial, tracheal, esophageal, and mediastinal veins
  - external vertebral venous plexus
  - v. intercostalis suprema et superior
  - v. thoracica interna
  - v. vertebralis, v. thyroidea inferior (plexus thyroideus impar), v. laryngea inferior

# REGIO PRAESTERNALIS

- extent of the sternum
- thick skin with numerous sweat and sebaceous glands; in men, hair
- minimal fat in the subcutaneous tissue
- the periosteum of the sternum merges with the radiate sternocostal ligament
- on the dorsal surface of the sternum, the transverse thoracic muscle
- the endothoracic fascia

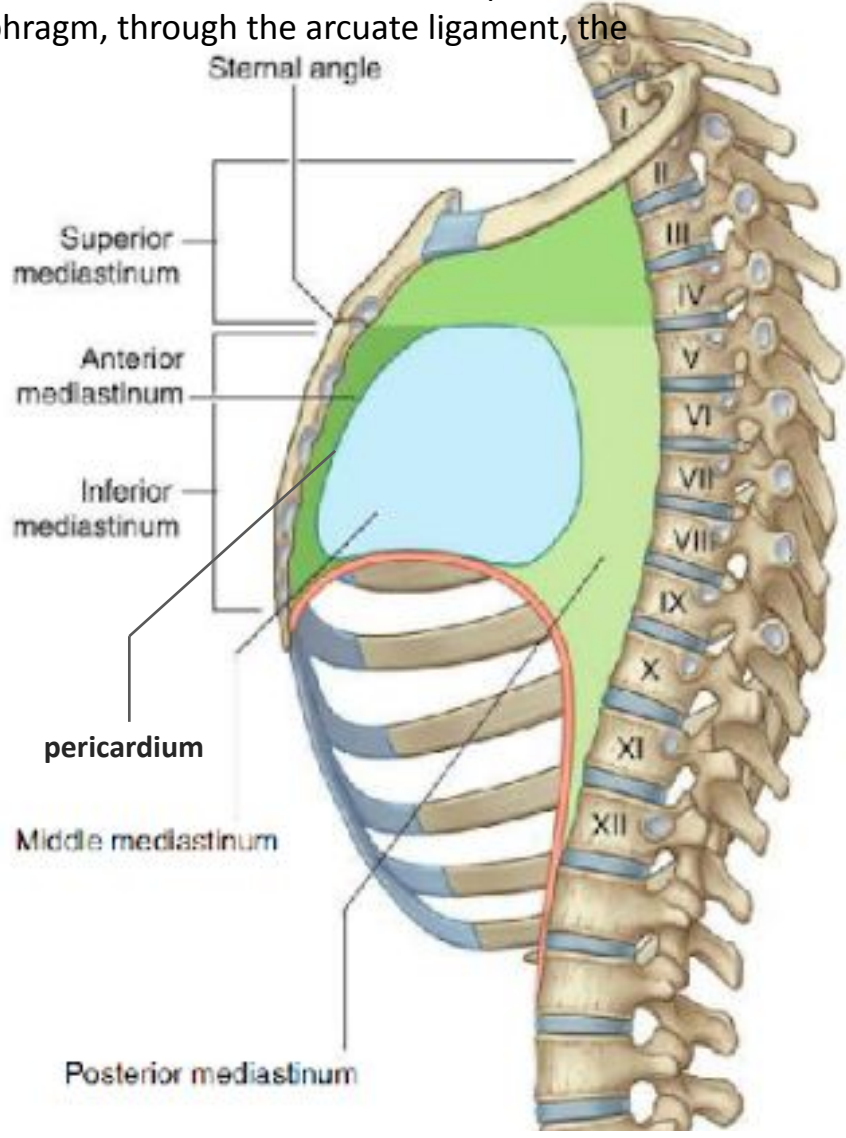
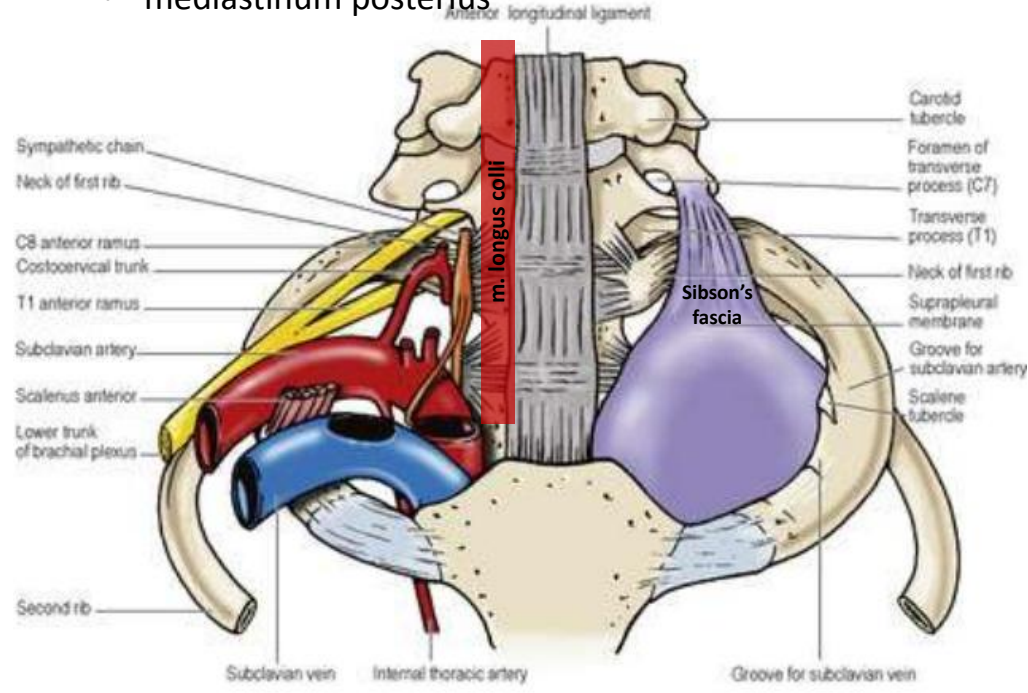
# REGIO PECTORALIS, TRIGONUM CLAVIPECTORALE

- Extent of the pectoralis major muscle
- In men, hair
- In the subcutaneous tissue: supraclavicular nerves
  - deltoideopectoralis sulcus with VCeph. extending into the clavipectoral triangle (clavipectoral fascia at the base), AThorAcr., pectoral nerves
  - the clavipectoral fascia contains both the MPMaj and MPMin
- beneath the fascia, a neurovascular bundle extends into the axilla
- in women, the mammary region is described (breast region)
  - skin with areola mammae
  - in the subcutaneous tissue: premammary fat in the mammary glands
  - retromammary fat connected to the pectoral fascia
  - medial mammary vessels (vasa ThorInt.) and lateral mammary vessels (vasa ThorLat., IntercostPost.)



# Structure of the thoracic cavity

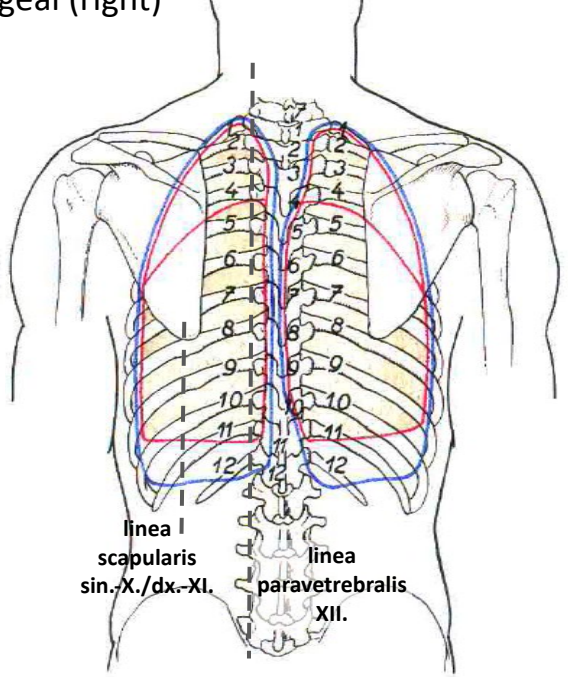
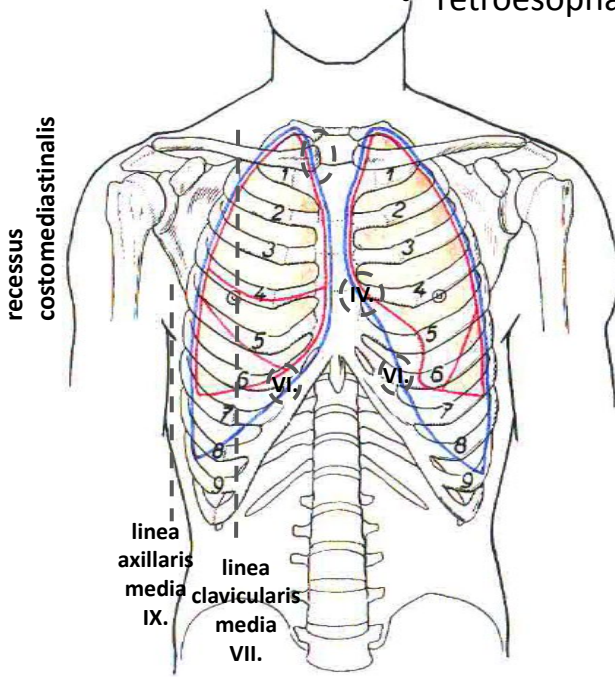
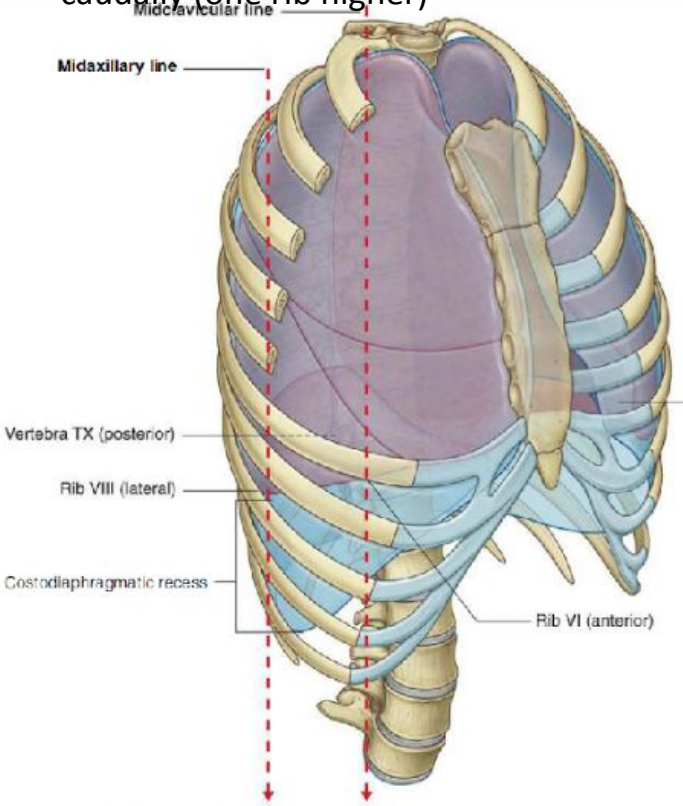
- The cavity is lined by the endothoracic fascia (from C7—Sibson’s fascia and the first ribs, from the prevertebral fascia, and from the transverse abdominal fascia—across the diaphragm, through the arcuate ligament, the aortic hiatus, and the esophageal hiatus)
- cavitas pleuralis dx. et sin.
- mediastinum
  - it connects cranially to the cervical visceral space
  - and is bounded caudally by the diaphragm
  - ventrally by the sternum and costal cartilages
  - and dorsally by the spine
- mediastinum superius
- mediastinum inferius
  - mediastinum anterius
  - mediastinum medius
  - mediastinum posterius



# Borders and projections of the lungs and the parietal pleura

- cupula → lesser supraclavicular fossa
- ventral border and projection → from the sternocostal joint to the level of the 6th sternocostal joint, between the right and left pleura: superior and inferior interpleural areas
- caudal border and projection → from the 4th rib diverging, the cartilage of the 7th rib and the medioclavicular artery, the 9th rib and the middle axillary artery, the 10th/11th ribs and the scapular artery, the 12th rib and the paravertebral artery
- dorsal border and projection → from C7 to Th12 paravertebrally, on the right the retroesophageal recess
- the borders of the lungs differ from the borders of the pleura caudally (one rib higher)

- a shiny, transparent serous membrane
- visceral pleura
  - firmly adherent to the surface of the lungs
  - extending into the interlobar spaces
- mesopneumonia around the pulmonary hilum
- parietal pleura (parietal pleura)
  - cupula pleurae
  - pleura costalis
  - pleura mediastinalis
  - pleura diaphragmatica
- pleural recesses
  - costodiaphragmatic
  - costomediastinal
  - phrenicomediastinal
  - retroesophageal (right)

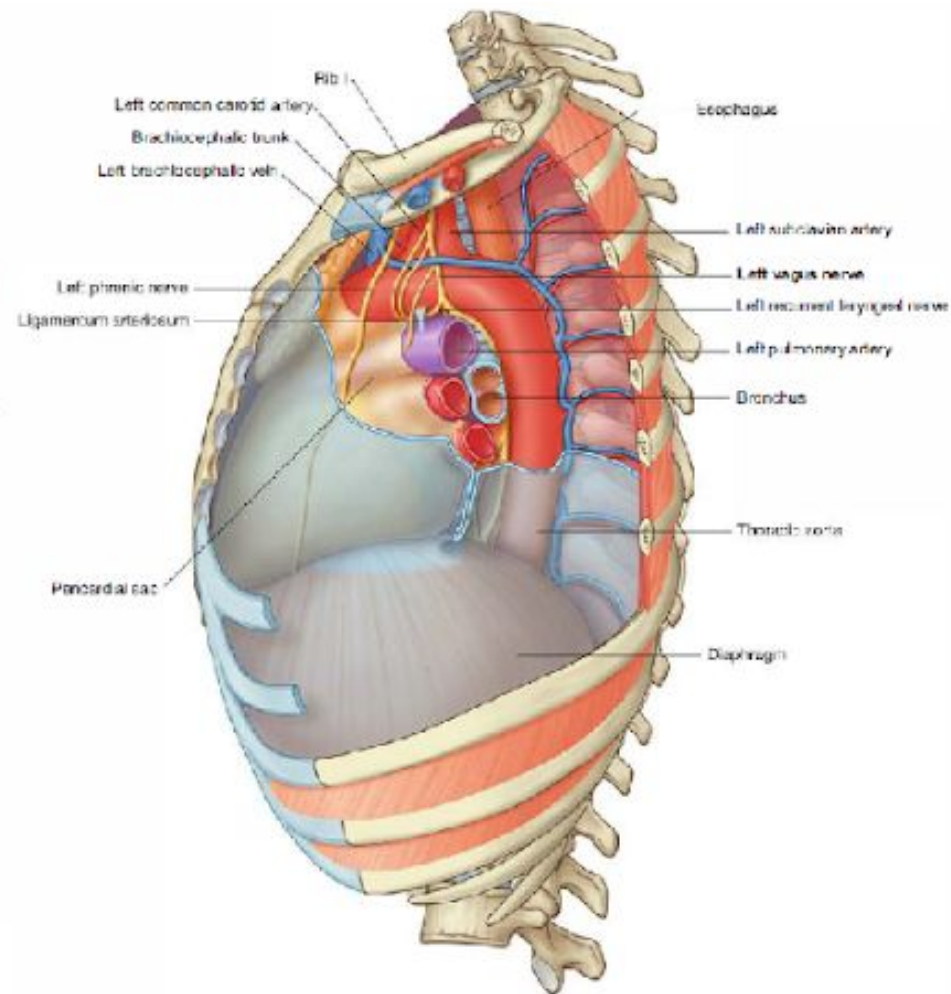
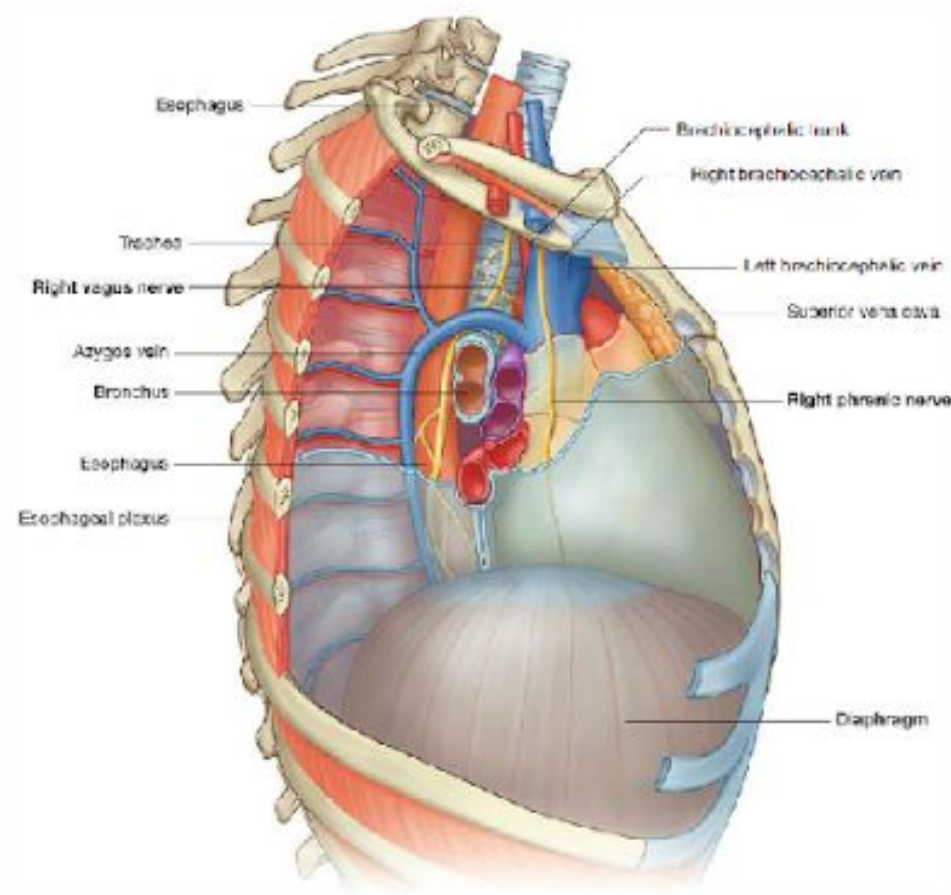


# MEDIASTINUM

- superior mediastinum
  - remnants of the **thymus** with fat
  - **SVC, brachiocephalic veins** with tributaries
  - **phrenic nerve** (runs in front of the pulmonary hilum), **vagus nerve** (runs into the posterior mediastinum behind the pulmonary hilum) gives off the recurrent laryngeal nerve
  - ascending **aorta**, aortic arch (curves into the posterior mediastinum) with branches
  - in the aortic arch, pulmonary trunk with pulmonary arteries
  - **trachea** with **bronchi** and bronchopericardial membrane
  - **esophagus**
- inferior mediastinum, anterior portion
  - between the anterior surface of the pericardium and the posterior surface of the sternum
  - sternopericardial ligament, **internal thoracic vessels**, parasternally located lymph nodes
- inferior mediastinum, middle part
  - **heart** within the pericardium, phrenic nerve with pericardiophrenic vessels
- inferior mediastinum, posterior part
  - between the posterior surface of the pericardium and the spine
  - **esophagus with the X nerves** (left in front) and the esophageal plexus
  - from Th3, the thoracic aorta runs from the left toward the esophagus
  - before entering the esophagus at the esophageal hiatus, it touches the posterior wall of the left atrium
  - the thoracic **aorta** gives off visceral (bronchial, pericardial, esophageal branches) and parietal branches (posterior intercostal arteries)
  - v. **azygos** – on the right side of the spine, runs posteriorly in an arc across the pulmonary hilum into the v. c. s., receives the v. hemiazygos at the level of Th7 to Th9 (dorsolaterally to the aorta)
  - **ductus thoracicus** – emerges with the hiatus aorticus and ascends between the aorta and the azygos vein, first behind the esophagus, then along its left side through the superior thoracic aperture, opening into the left venous angle
  - right and left **sympathetic trunks** – paravertebrally ventrally to the trunks of the intercostal vessels; the splenic nerves run through the diaphragm into the retroperitoneum

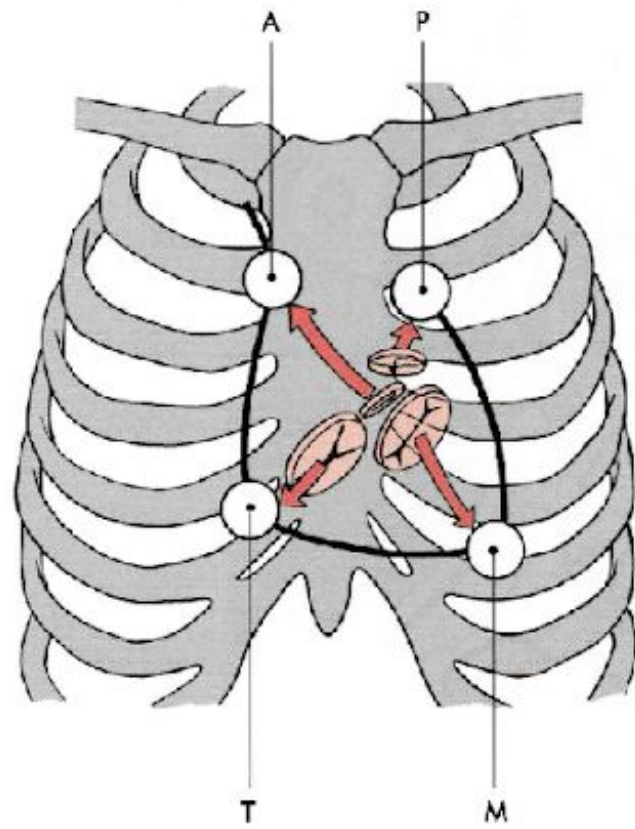
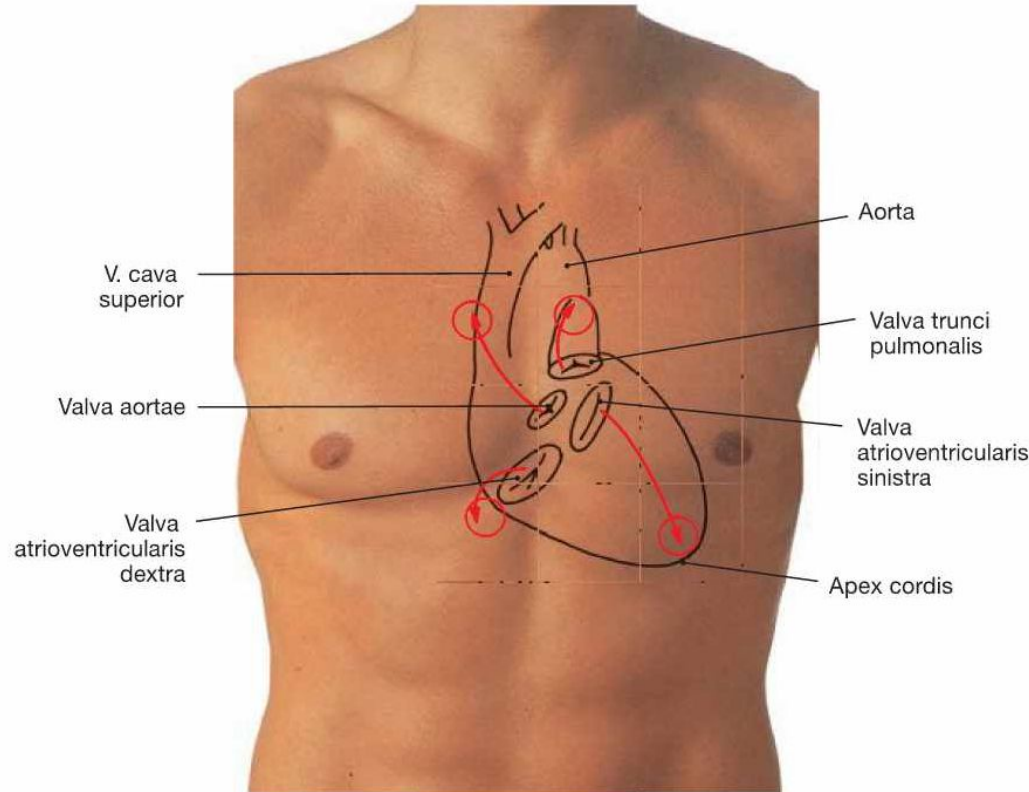
aorta
oesophagus
trachea/bronchi
n. vagus
n. phrenicus
s. v. c.
v. azygos
v. hemiazygos

# THORACIC CAVITY



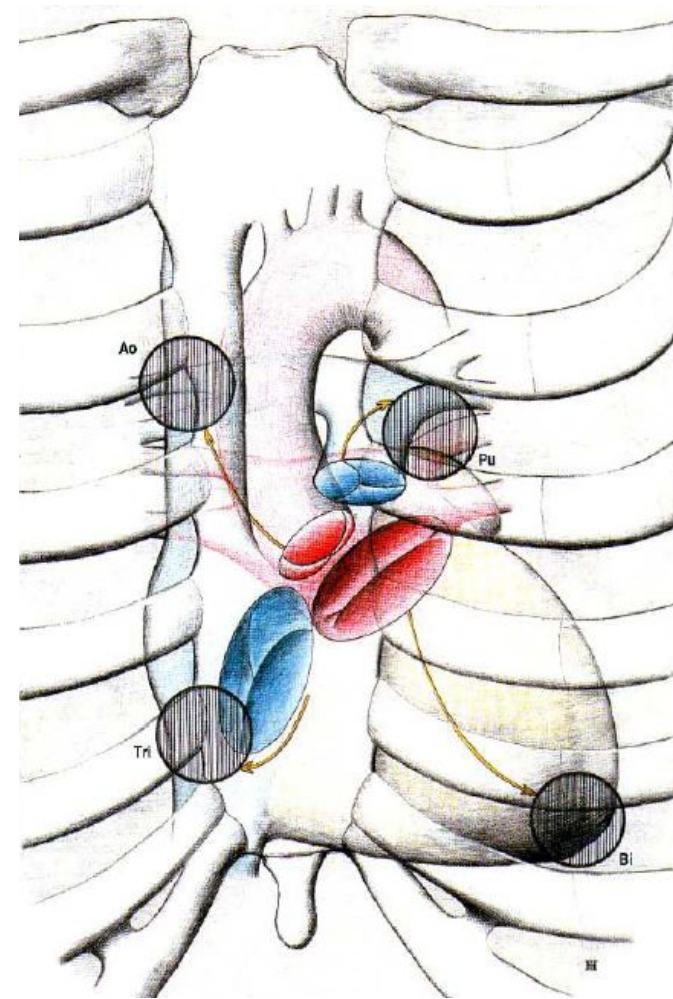
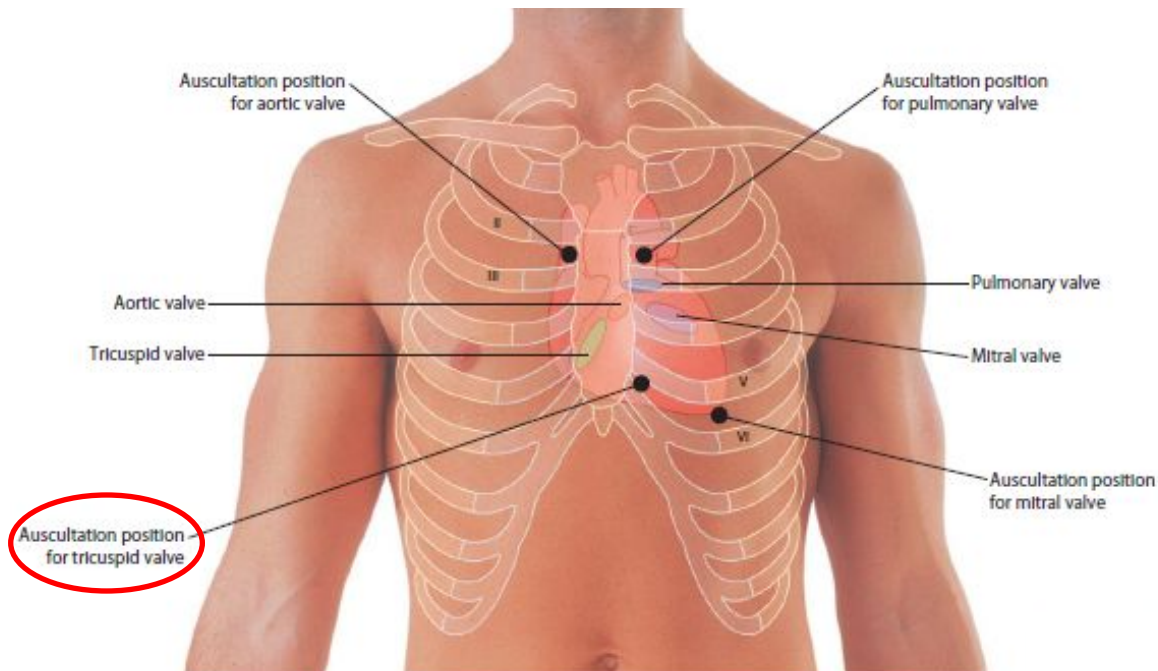
# Location and projection of the heart

- located in the mediastinum behind the sternum (1/3 to the right, 2/3 to the left)
- longitudinal axis of the heart
  - opening of the aorta → apex of the heart
- point A (2nd intercostal space, 1 cm to the right of the sternum), T (5th intercostal space at the right margin of the sternum), M (5th intercostal space on the left, medial to the midclavicular line or 8–9 cm from the midline), P (2nd intercostal space, 2 cm to the left of the sternum)
- position of the heart in the chest depends on
  - age, position of the diaphragm, respiratory movements, shape of the chest, body position

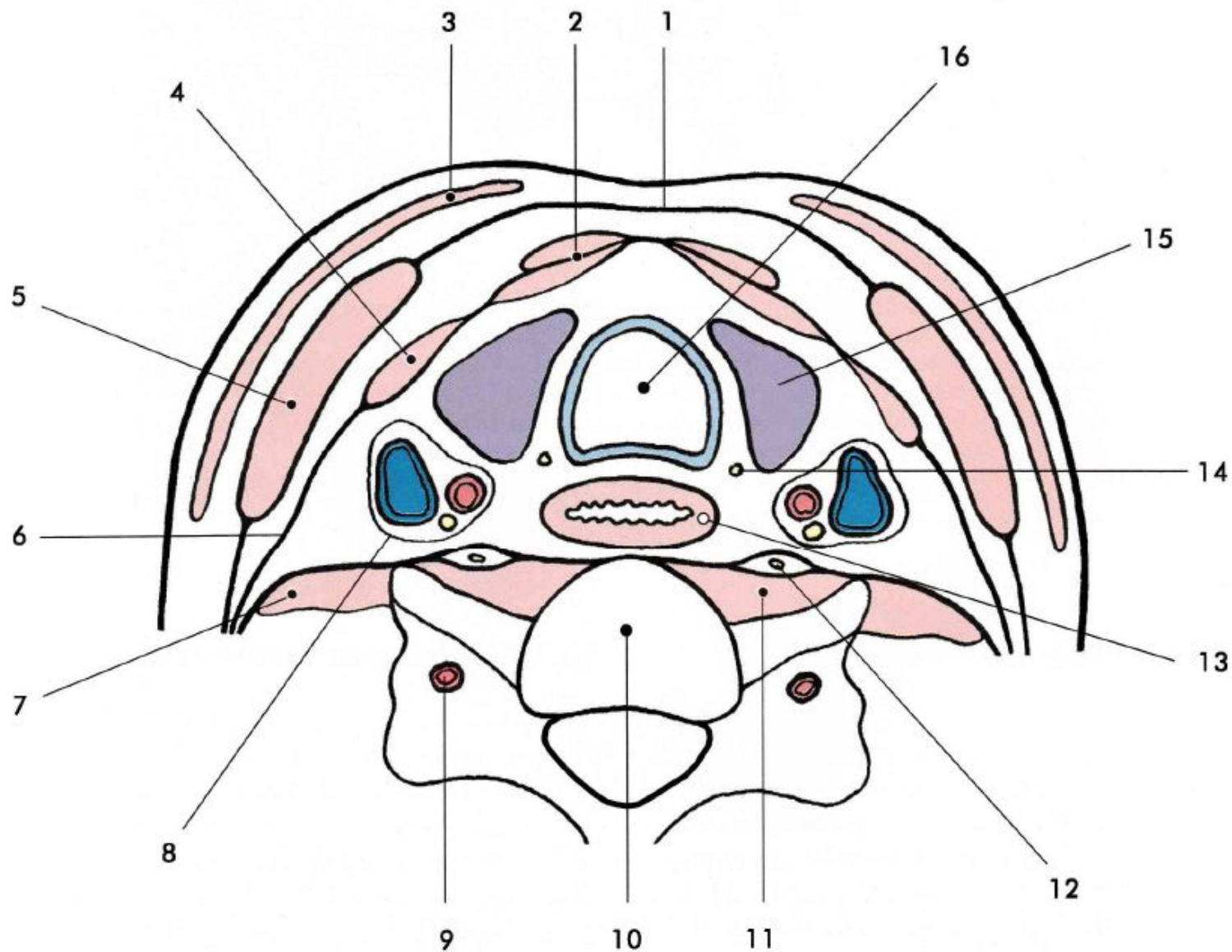


# Auscultation points

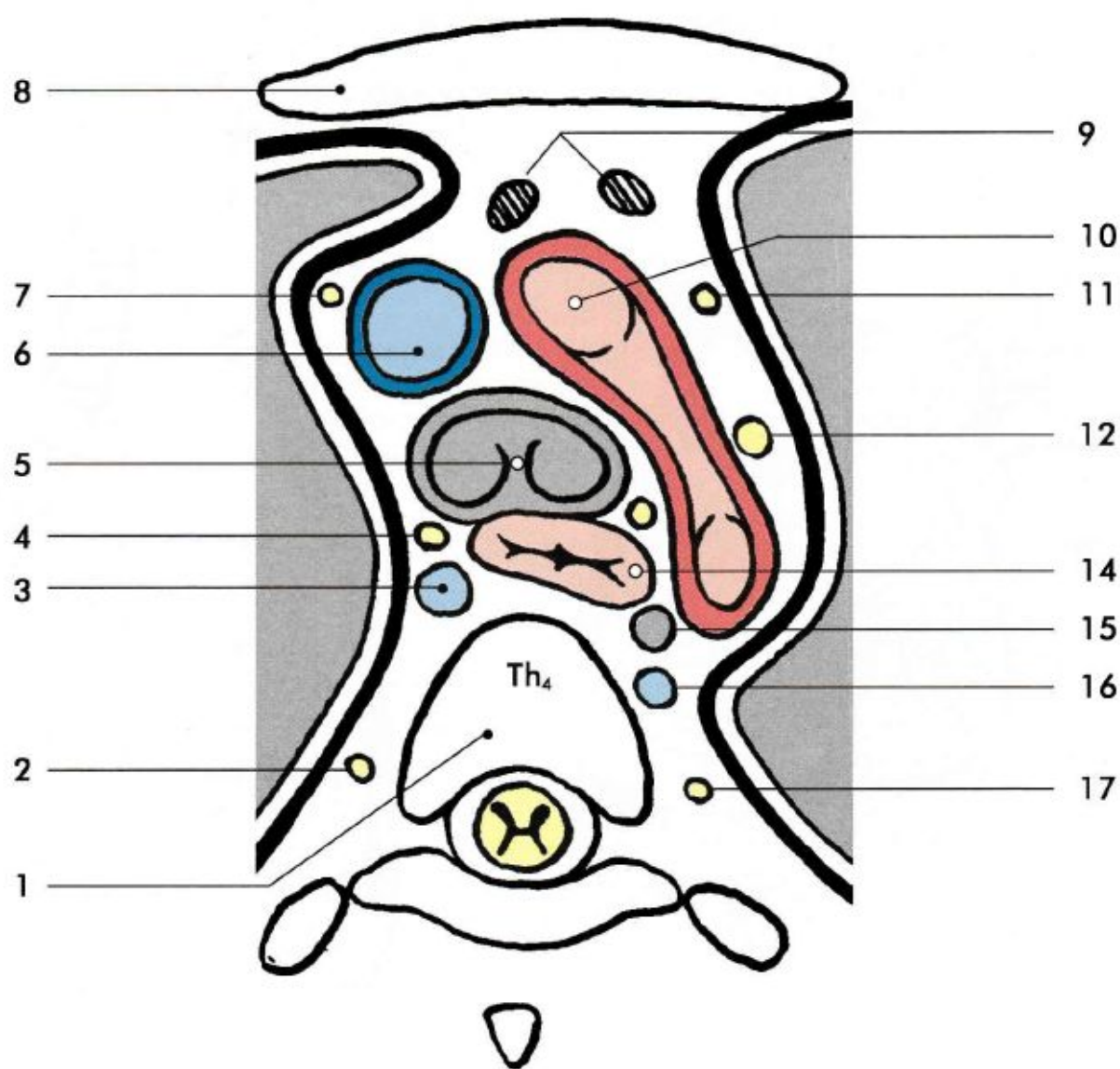
- projection does not correspond to the auscultation



*pro trojcípou chlopeň – místo 5. sternokostálního kloubu vpravo;*  
*pro dvojcípou chlopeň – místo projekce hrotu srdečního (viz výše);*  
*pro pulmonální chlopeň – 2. mezižebří vlevo u ster-na;*  
*pro aortální chlopeň – 2. mezižebří vpravo u ster-na.*

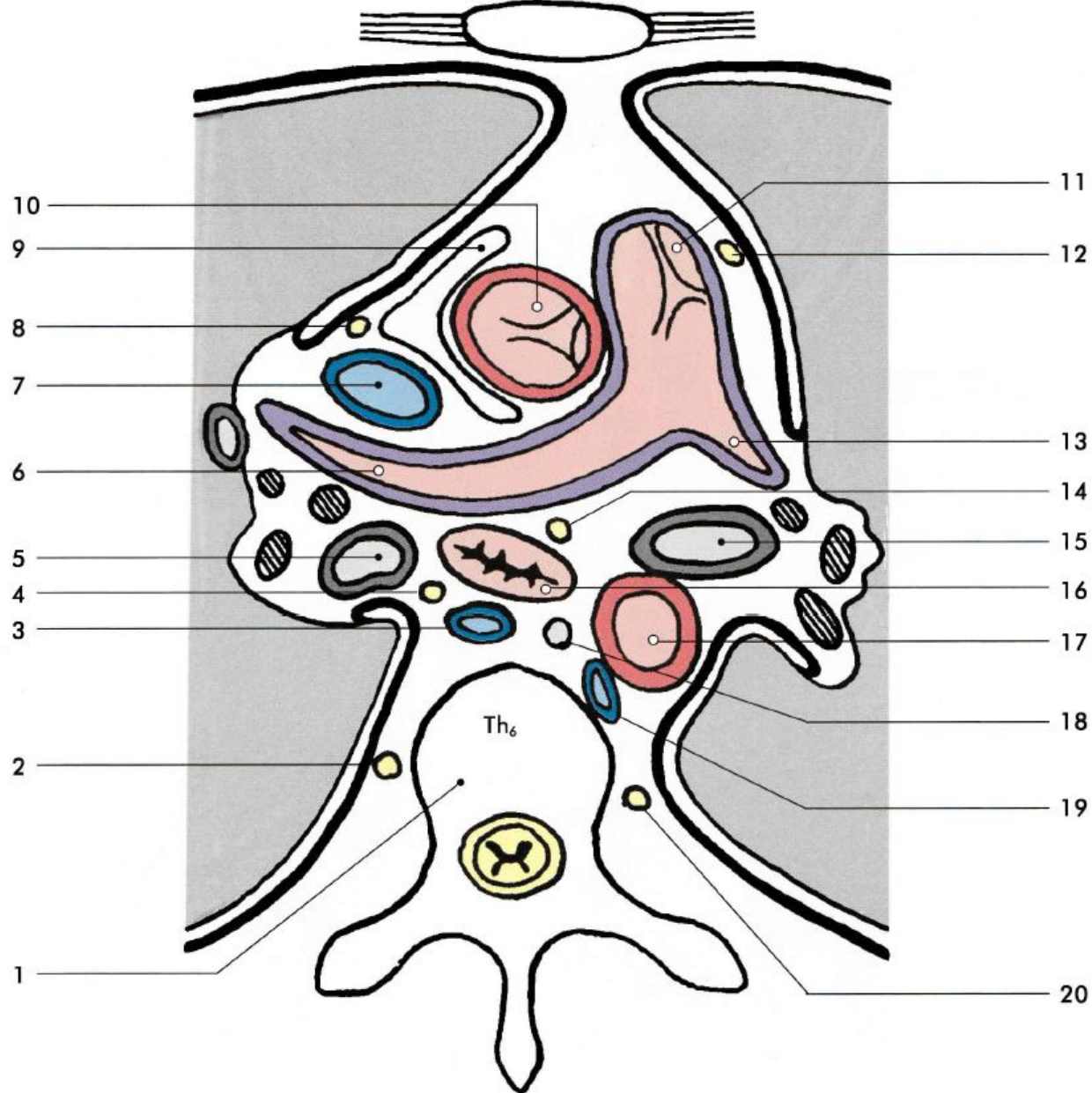


**Obr. 14.10. Schéma příčného řezu krkem ve výši těla C<sub>6</sub>.** 1 – lamina spf. fasciae cervicalis, 2 – m. sternohyoideus et m. sternothyroideus, 3 – platysma, 4 – m. omohyoideus, 5 – m. sternocleidomastoideus, 6 – lamina pretrachealis fasciae cervicalis, 7 – mm. scaleni, 8 – nervově-cévní svazek krční ve vagina carotica, 9 – a. vertebralis, 10 – tělo obratle C<sub>6</sub>, 11 – m. longus colli, 12 – truncus sympathicus, 13 – oesophagus, 14 – n. laryngeus recurrens, 15 – glandula thyroidea, 16 – trachea

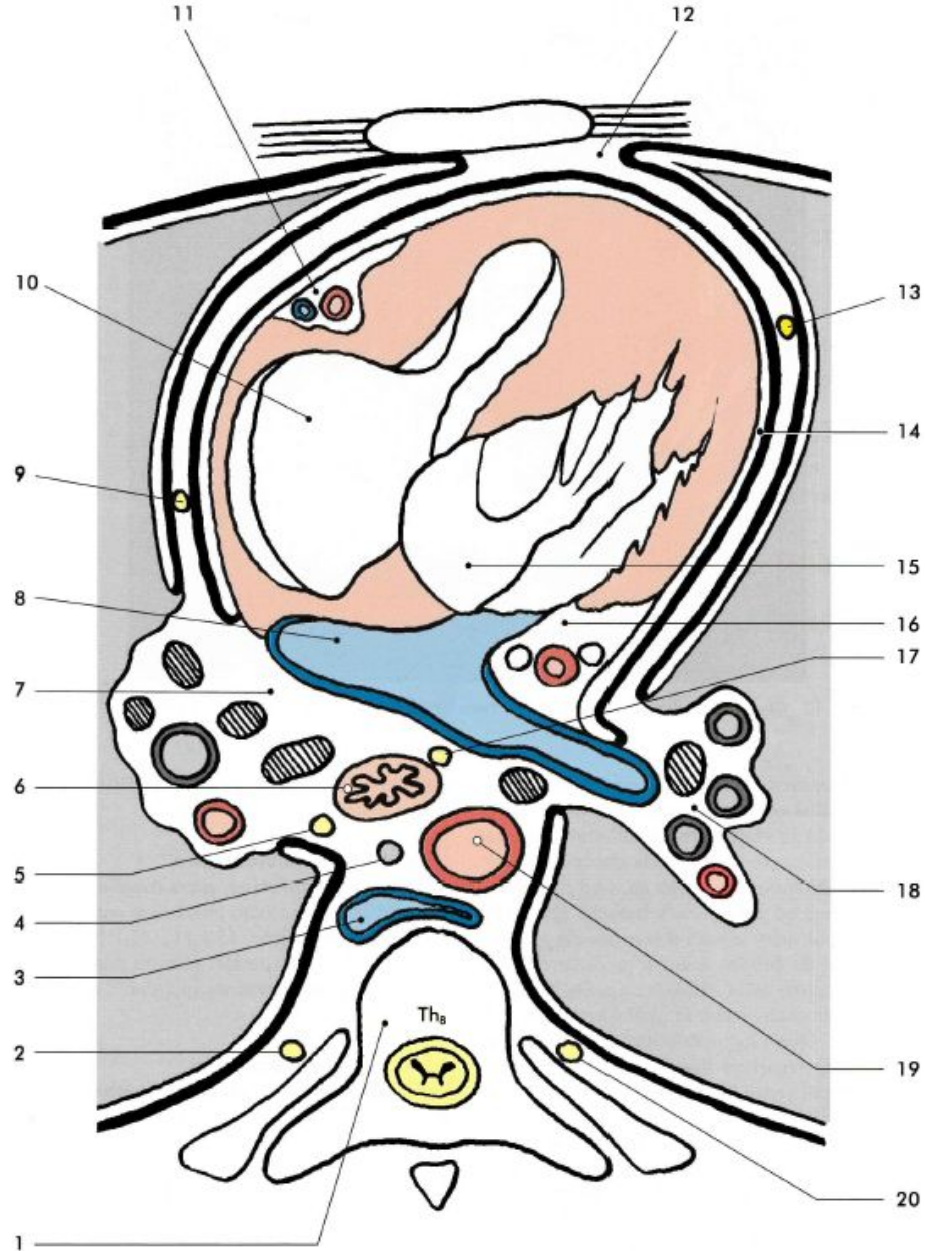


Obr. 15.1.8. Schéma příčného řezu hrudníkem ve výši těla Th<sub>4</sub>, pohled zespodu. 1 – corpus vertebrae Th<sub>4</sub>, 2 – truncus sympathicus dx., 3 – v. azygos, 4 – n. vagus dx., 5 – bifurcatio tracheae, 6 – v. cava sup., 7 – n. phrenicus dx., 8 – sternum, 9 – nodi lymphatici praepericardiales, 10 – arcus aortae, 11 – n. phrenicus sin., 12 – n. vagus sin., 13 – n. laryngeus recurrens sin., 14 – oesophagus, 15 – ductus thoracicus, 16 – v. hemiazygos access., 17 – truncus sympathicus sin.

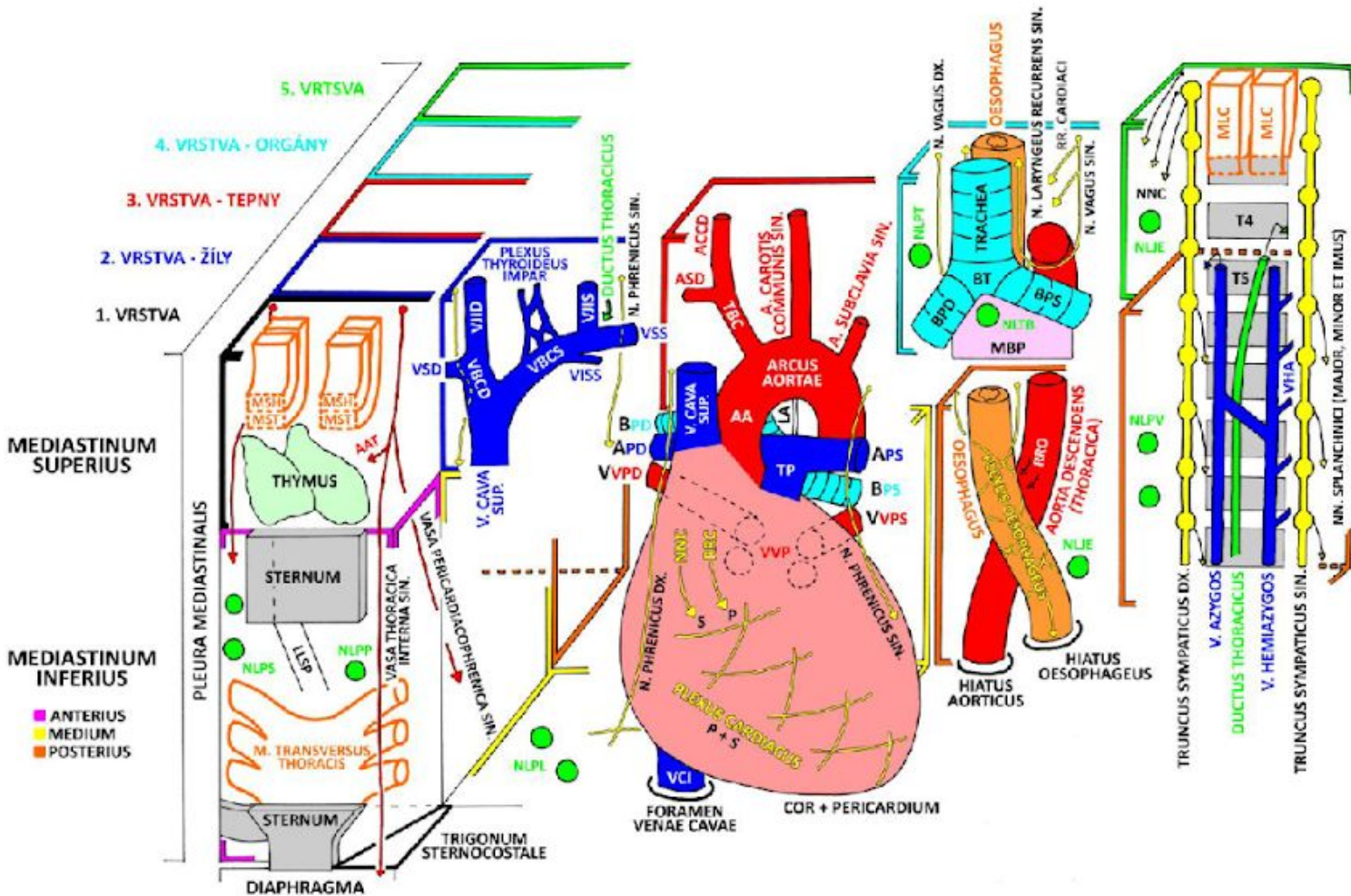
TH6



Obr. 15.1.9. Schéma příčného řezu hrudníkem ve výši těla Th<sub>6</sub>, pohled zespodu. 1 – corpus vertebrae Th<sub>6</sub>, 2 – truncus sympathicus dx., 3 – v. azygos, 4 – n. vagus dx., 5 – bronchus principalis dx., 6 – a. pulmonalis dx., 7 – v. cava sup., 8 – n. phrenicus dx., 9 – cavitas pericardiaca, 10 – aorta ascendens s valva aortae, 11 – truncus pulmonalis a valva trunci pulmonalis, 12 – n. phrenicus sin., 13 – a. pulmonalis sin., 14 – n. vagus sin., 15 – bronchus principalis sin., 16 – oesophagus, 17 – aorta descendens, 18 – ductus thoracicus, 19 – v. hemiazygos, 20 – truncus sympathicus sin.



Obr. 15.1.11. Schéma příčné řezy hrudníkem ve výši těla Th<sub>8</sub>, pohled zespodu. 1 – corpus vertebrae Th<sub>8</sub>, 2 – truncus sympathicus dx., 3 – v. azygos, 4 – ductus thoracicus, 5 – n. vagus dx., 6 – oesophagus, 7 – hilum pulmonis dx., 8 – v. pulmonalis dx., 9 – n. phrenicus dx., 10 – ventriculus dx., 11 – a. coronaria dx., 12 – mediastinum ant., 13 – n. phrenicus sin., 14 – cavitas pericardiaca, 15 – ventriculus sin., 16 – a. coronaria sin., 17 – n. vagus sin., 18 – hilum pulmonis sin., 19 – aorta descendens, 20 – truncus sympathicus sin.



MSH - M. STERNOHYOIDEUS  
MST - M. STERNOTHYROIDAEUS  
AAT - AA. THYMICAE

VSD - V. SUBCLAVIA DX.  
VIID - V. JUGULARIS INTERNA DX.  
VBOD - V. BRACHIOCEPHALICA DX.  
VBOS - V. BRACHIOCEPHALICA SIN.  
VIIS - V. JUGULARIS INTERNA SIN.  
VSS - V. SUBCLAVIA SIN.  
VISS - V. INTERCOSTALIS SUP. SIN.

ASD - A. SUBCLAVIA DX.  
ACCD - A. CAROTIS COMMUNIS DX.  
TBC - TRUNCUS BRACHIOCEPHALICUS

BT - BIFURCATIO TRACHEAE  
BPD - BRONCHUS PRINCIPALIS DX.  
BPS - BRONCHUS PRINCIPALIS SIN.  
MBP - MEMBRANA BRONCHOPERICARDIACA  
NLPT - N. L. PARATRACHEALES  
NLTB - N. L. TRACHEOBRONCHIALES

MLC - M. LONGUS COLLI  
NNC - NN. CARDIACI  
NLJE - N. L. JUXTAESOPHAGEALES

LLSP - LIGG. STENROPERICARDIACA  
NLPS - N. L. PARASTERNALES  
NLPP - N. L. PREPERICARDIACI

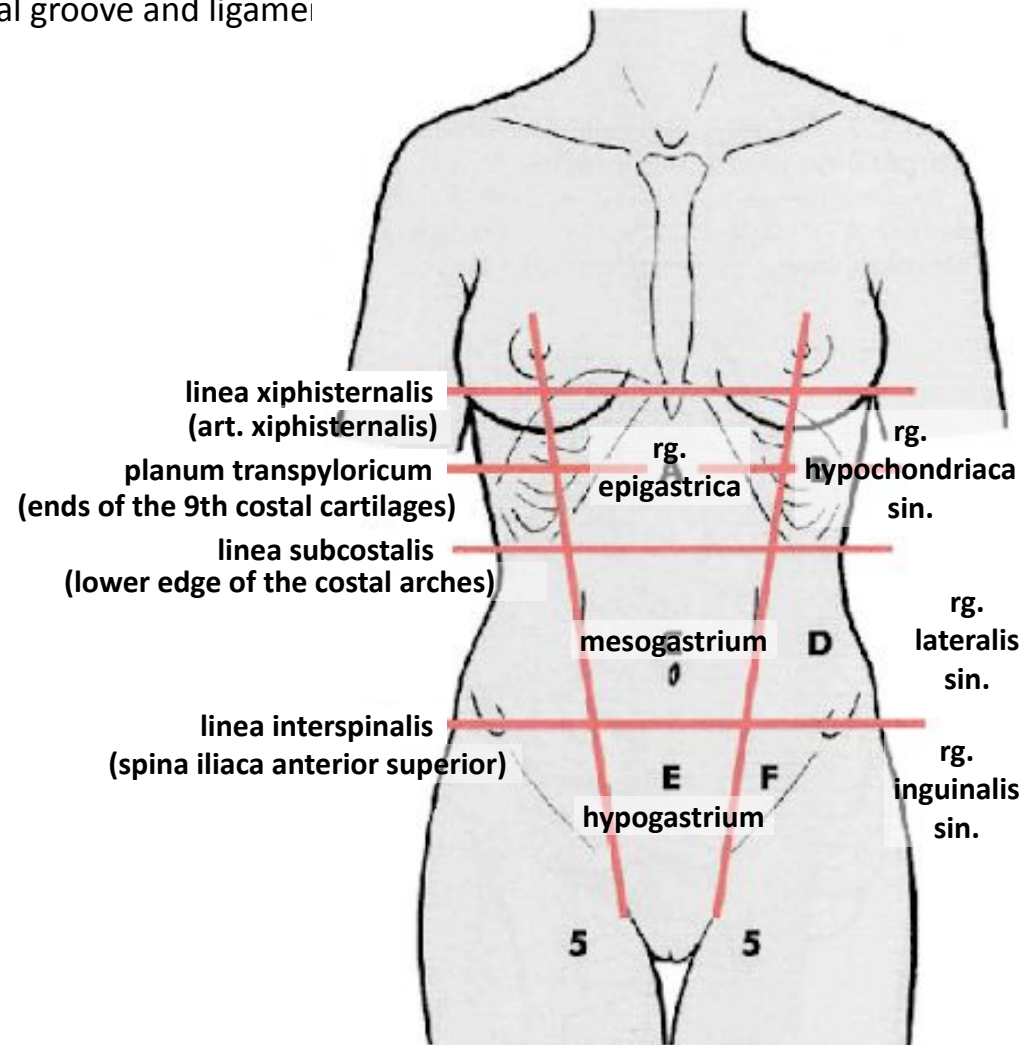
APD - A. PULMONALIS DX.  
VVPD - VV. PULMONALES DX.  
AA - AORTA ASCENDENS  
TP - TRUNCUS PULMONALIS  
LA - LIG. ARTERIOSUM  
APS - A. PULMONALIS SIN.  
VVPS - VV. PULMONALES SIN.  
RR - RR. CARDIACI  
VCI - V. CAVA INF.  
NLPL - N. L. PERICARDIACI LATERALES

RRO - RR. OESOPHAGEI

NLPV - N. L. PREVERTEBRALES  
VHA - V. HEMIAZYGOS ACCESSORIA

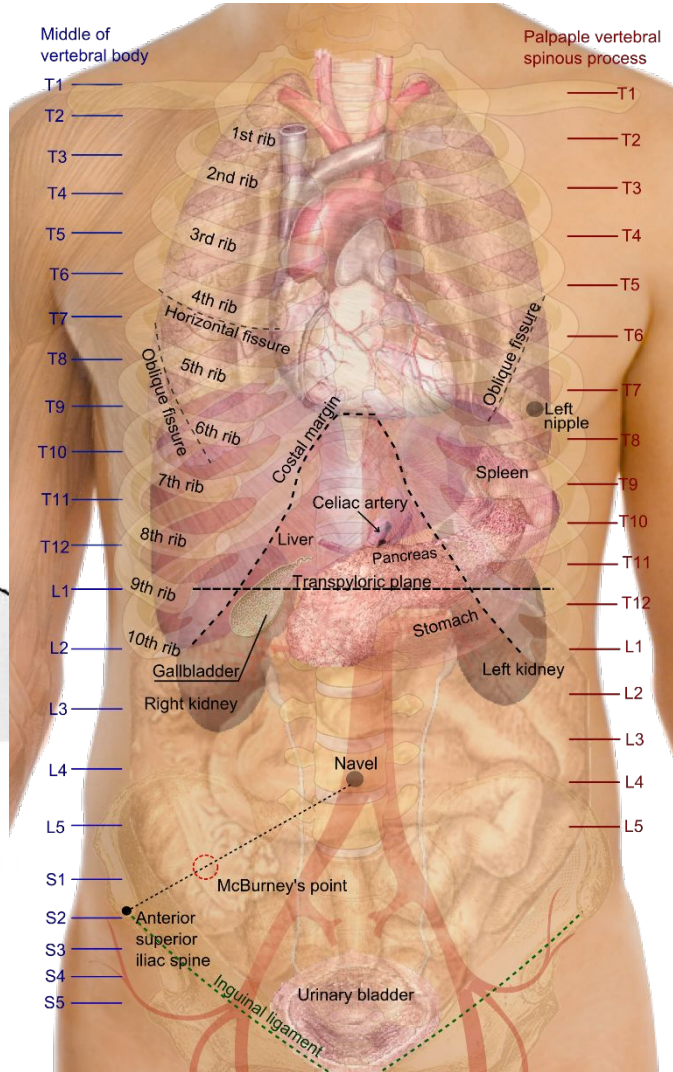
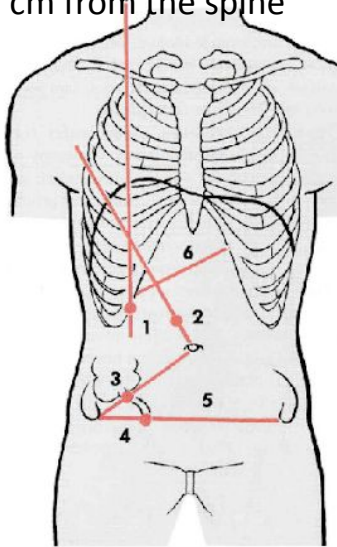
# Abdominal regions

- against the chest
  - superficially: xiphoid process – costal arch – spinous process of Th12
  - inferior thoracic aperture = costal arches – last ribs – body of Th12
  - deeply: diaphragm (projects to the 4th intercostal space on the right, to the 5th intercostal space on the left) – linea xiphisternalis
- against the lower limb
  - crista iliaca, spina iliaca anterior superior, inguinal groove and ligament
- horizontal auxiliary superficial planes and lines
  - linea xiphisternalis
  - transpyloric plane
  - subcostal plane – subcostal line
  - interspinal plane – interspinal line
- vertical auxiliary lines
  - location varies by source
  - medioclavicular line
- regions
  - epigastric, laterally hypochondriac
  - umbilical (mesogastrium), laterally lateral
  - pubica (hypogastrium), laterally inguinales



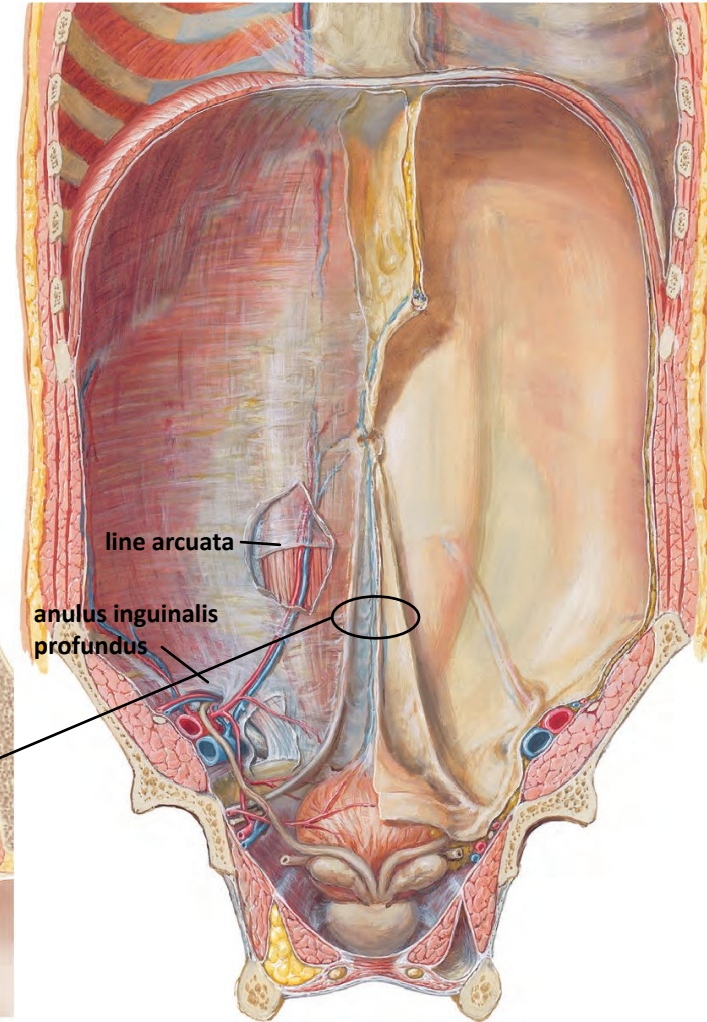
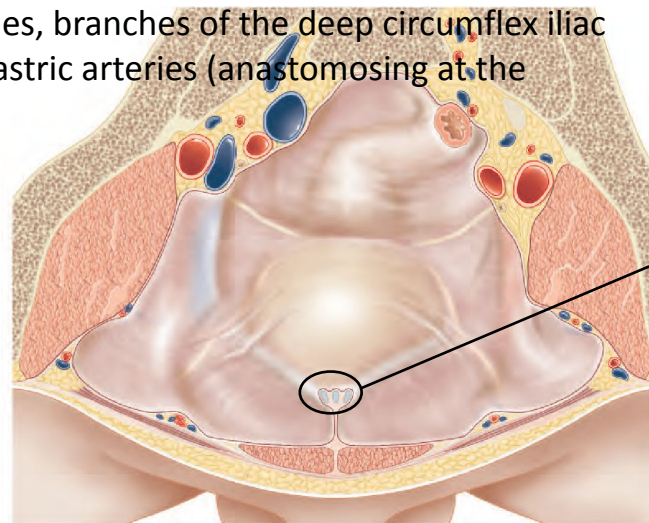
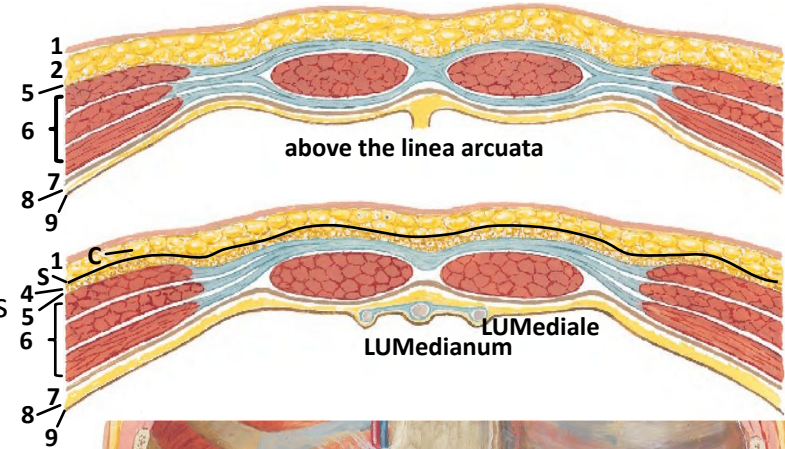
# Projection of organs on the anterior abdominal wall

- Liver
  - right hypochondrium
  - lower margin along the right costal arch; between the right midclavicular line and the left 8th costal cartilage, it touches the abdominal wall; further to the left beyond the costal arch
- Gallbladder
  - fundus to Murphy's point (1)
- Stomach
  - Labbé's triangle (liver margin–left costal arch–transpyloric line)
  - cardia to the left of Th11, pylorus to the right of L1–L2
- Spleen
  - longitudinal axis lies along the 10th rib
- duodenum, head of the pancreas, major duodenal papilla
  - wraps around L2
  - Desjardins' pancreatic point (2), 6 cm from the umbilicus
- caecum
  - medial to the anterior superior iliac spine
- vermiform appendix
  - origin from the caecum – McBurney's point (3), 6 cm from the spine
  - pelvic position – Lanz's point (4)

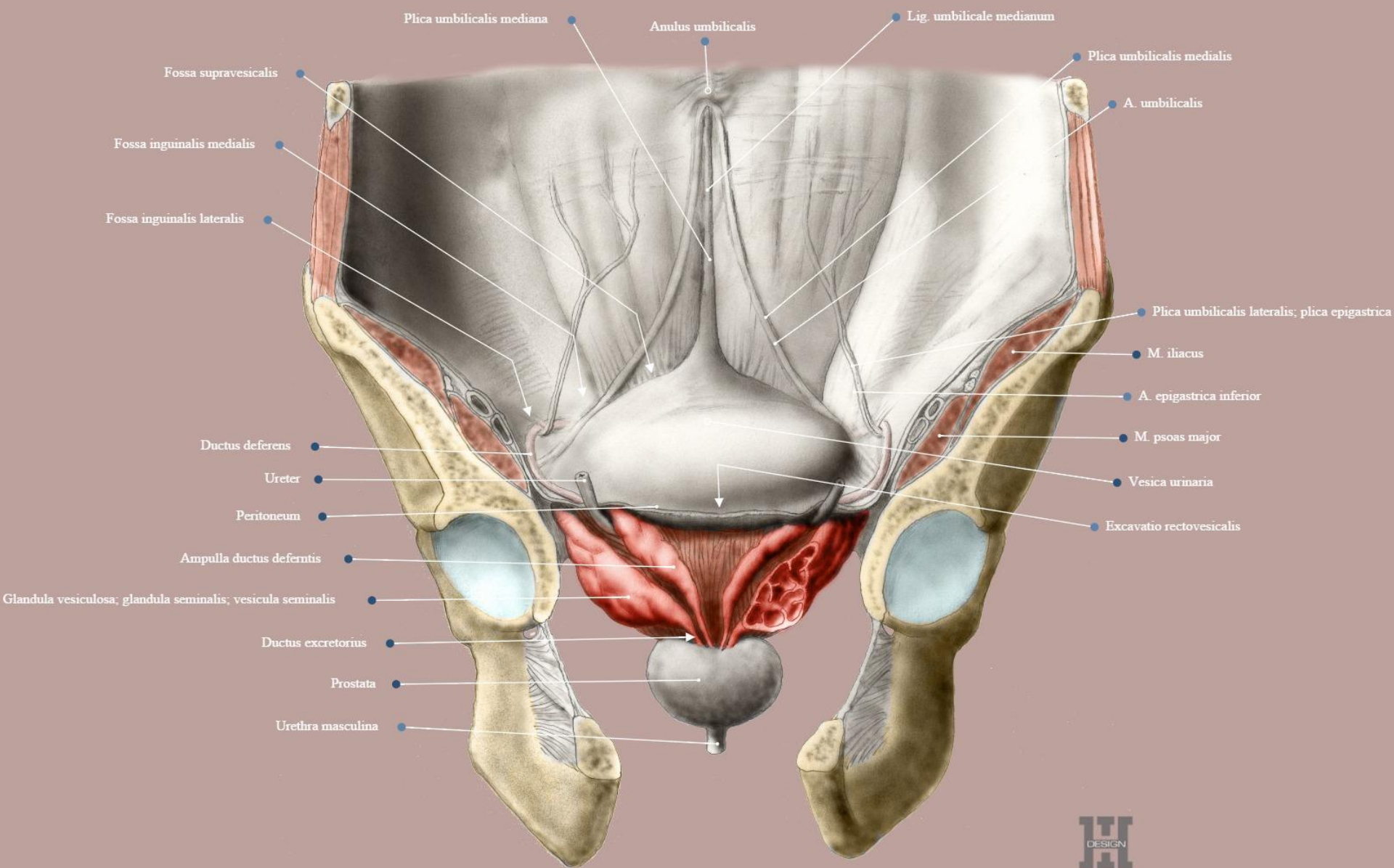


# Structure of the abdominal wall

- 1. skin
- 2. subcutaneous tissue with fat (caudally, Camper's layer, (C))
- vv. thoracoepigastricae, v. epigastrica spf.; a. epigastrica spf., a. circumflexa ilium spf., deeper: superficial branches of the posterior intercostal arteries, subcostal artery, lumbar arteries; intercostal nerves (last 5 pairs), subcostal nerve, inguinal nerve—branches of the iliohypogastric and ilioinguinal nerves
- 3. Fascia of Scarpa (S) – below the linea arcuata
  - across the inguinal ligament to the thigh into the fascia lata, medio-caudally into the fascia perinei spfc.
- 4. adipose layer
- 5. superficial abdominal fascia
- 6. muscles with their fasciae (intercostal nerves, iliohypogastric nerve, ilioinguinal nerve)
  - MOEA
  - MOIA
  - MRA, linea alba with anulus umbilicalis, linea arcuata
  - nerves
  - MTA
- intercostal arteries, lumbar arteries, branches of the deep circumflex iliac artery, superior and inferior epigastric arteries (anastomosing at the umbilicus)
- 7. transversalis fascia
- 8. adipose tissue
- 9. peritoneum

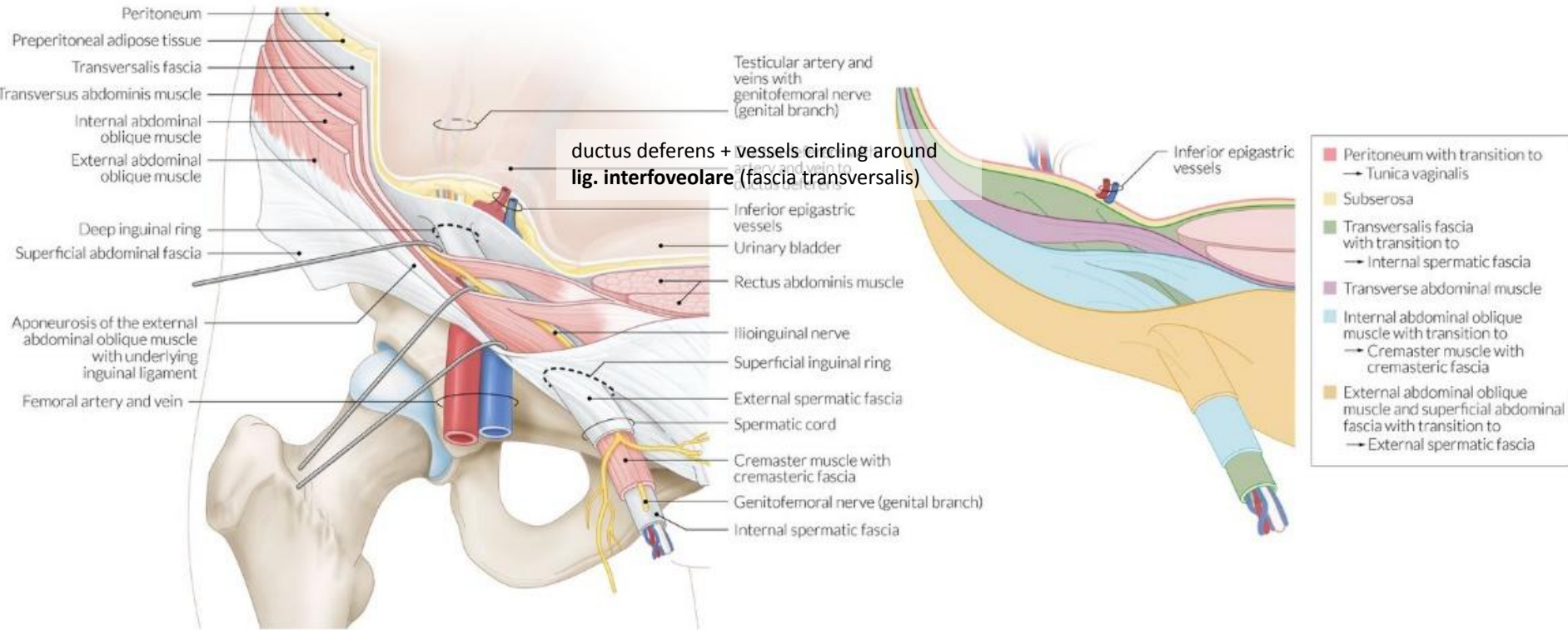


# PERITONEUM on the anterior abdominal wall

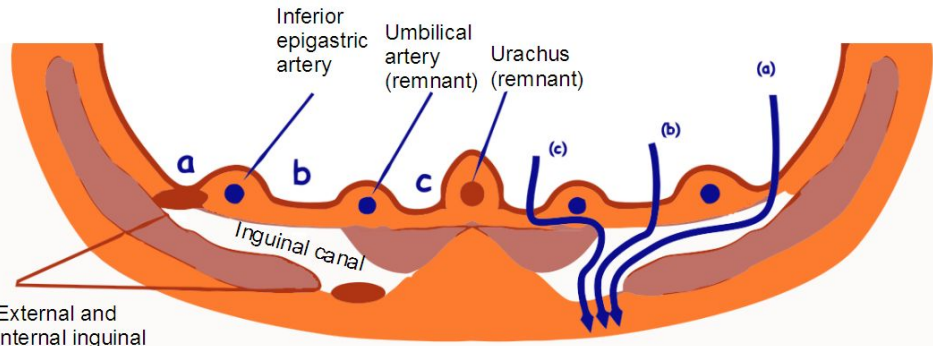


# REGIO INGUINALIS

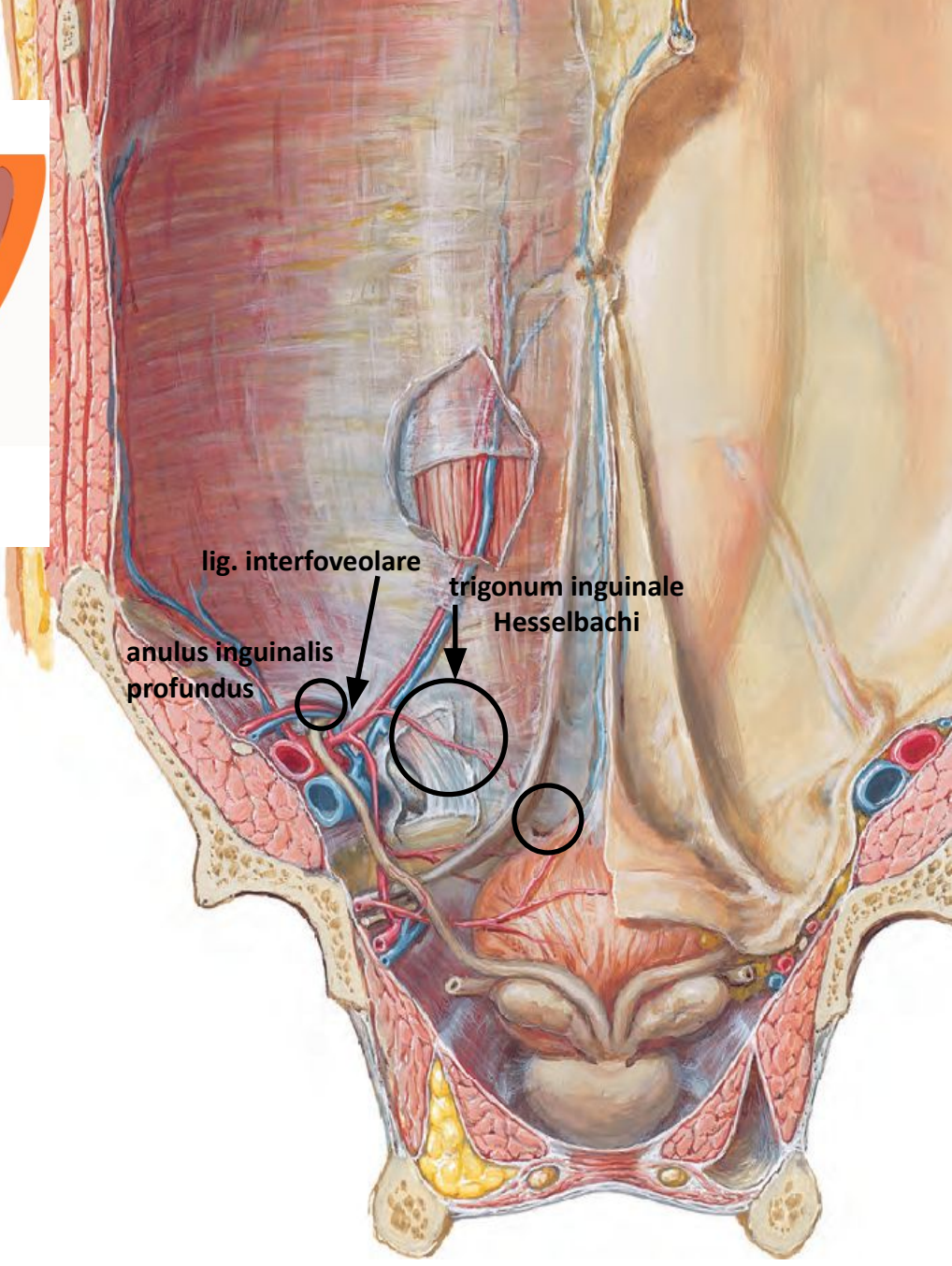
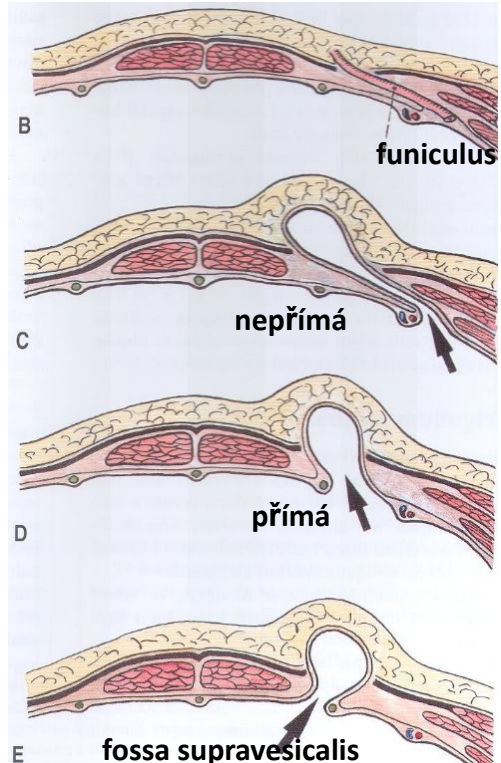
- canalis inguinalis (n. ilioinguinalis, r. genitalis n. gntfm., ♀ lig. teres uteri, ♂ funiculus spermaticus)
  - bottom: lig. inguinale (end of the aponeurosis MOEA)
  - ventral wall: fascia abd. spf. + aponeurosis of MOEA (anulus inguin. spf.)
    - ↳ crus mediale
    - ↳ crus laterale
  - ventral wall (1./3), roof, dorsal wall (3./3): MOIA+MTA
    - ↳ falx inguinalis (=tendo conjunctivus)
    - ↳ m. cremaster
  - dorsal wall: fascia transversalis (anulus inguin. prof.)
- In men, the fascia of Scarpa extends to the penis as the fascia of the penis, to the scrotum as the tunica dartos, to the perineal region as Colles' fascia, and to the thigh as the fascia lata
- funiculus spermaticus
  - FSE=FAS, MC+fascia cremasterica=MOIA+MTA, FSI=fascia transversalis



# Inguinal hernia

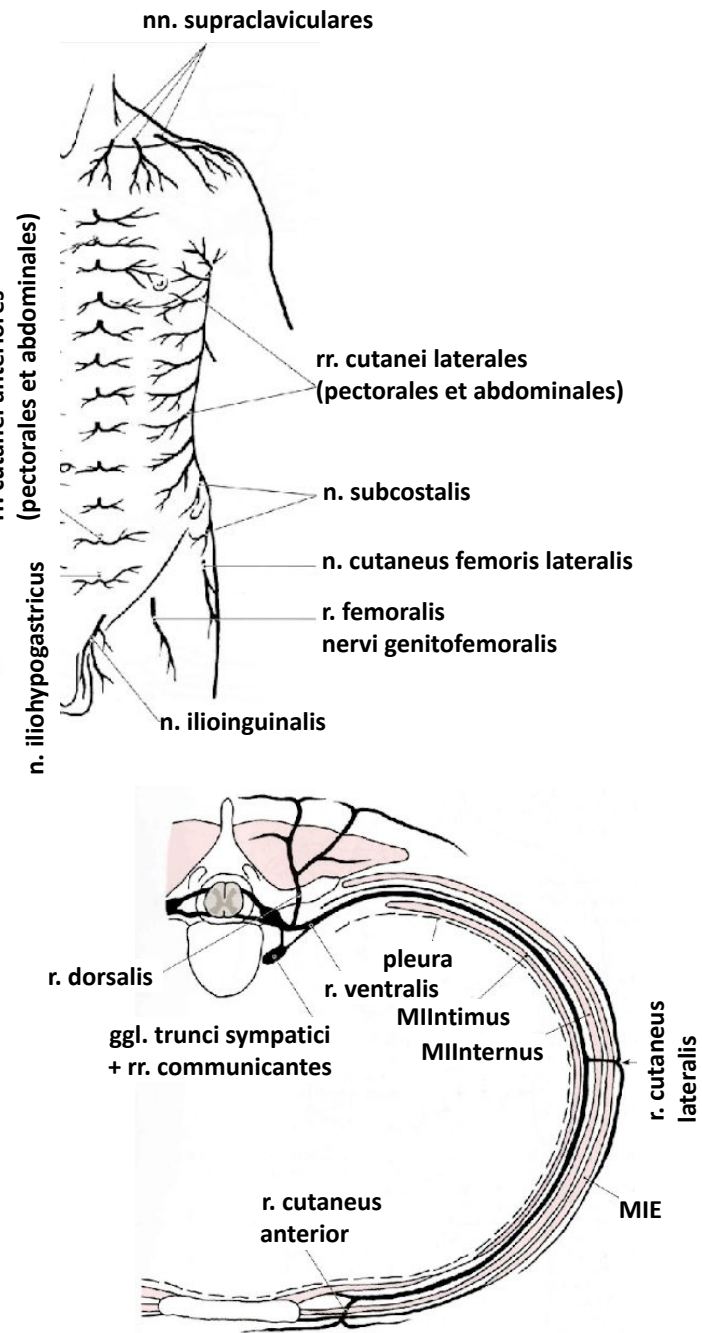
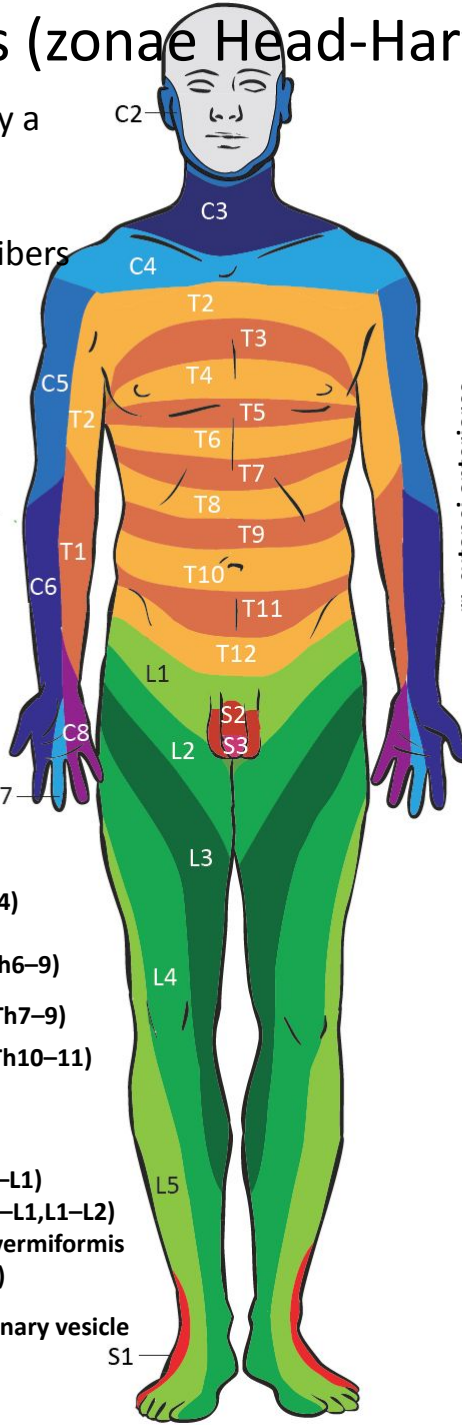
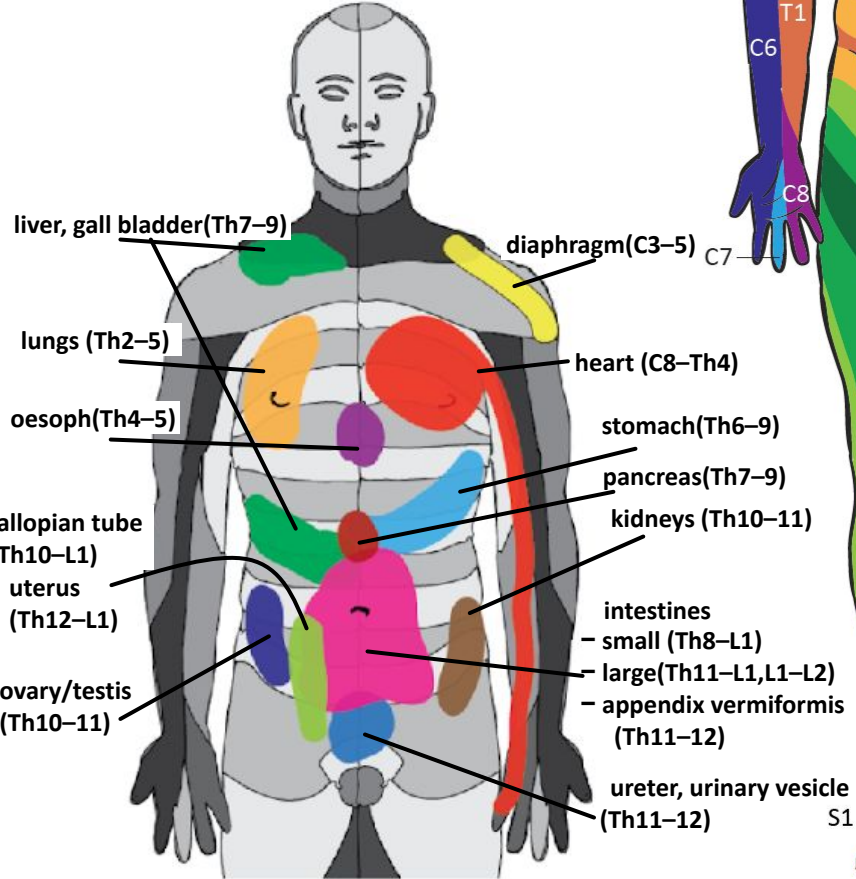


- a) lateral fossa
- b) medial fossa
- c) supravesical fossa



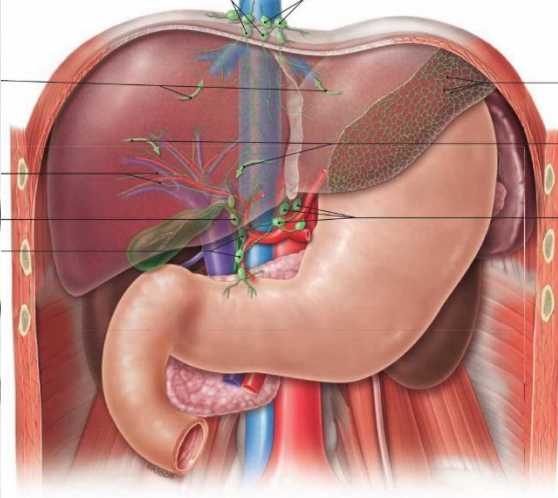
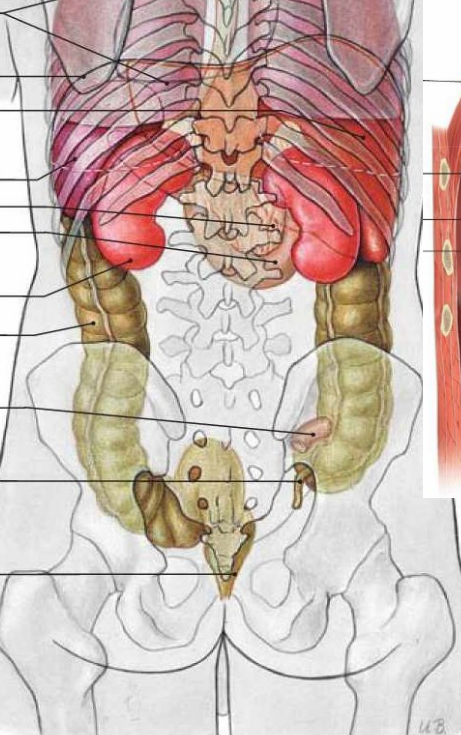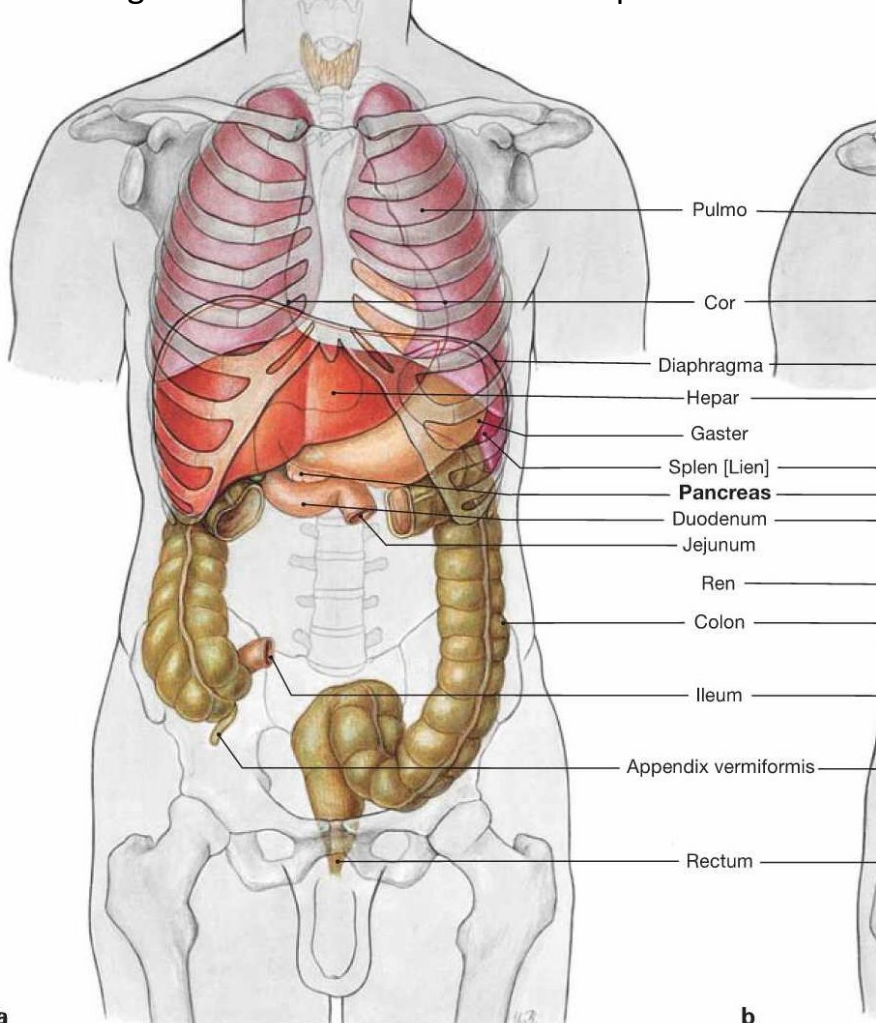
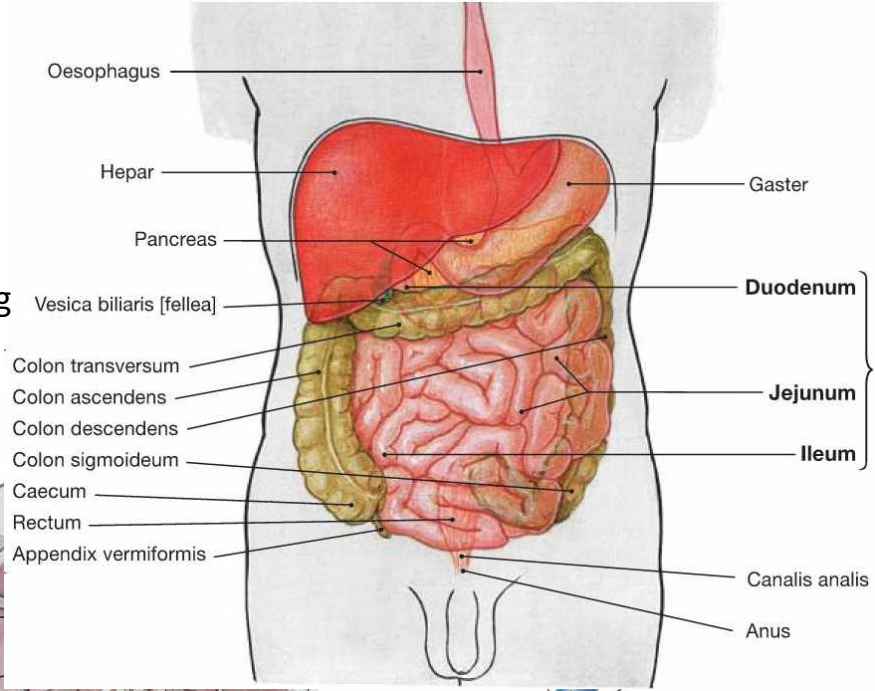
# Dermatomes and Head zones (zonae Head-Harteli)

- A dermatome is an area of skin innervated by a specific spinal nerve
- A visceral root area is an organ (or part of an organ) that is innervated by viscerosensory fibers from a single dorsal root
- In certain diseases, some skin areas become hypersensitive to touch



# CAVITAS ABDOMINALIS

- lined by the parietal peritoneum – peritoneal cavity
  - supramesocolic space with the omental bursa
  - inframesocolic space covered by the greater omentum; the posterior surface is divided by the mesentery into right and left adnexal fields; the ascending and descending colon adhere to the parietal peritoneum and separate the right and left external mesocolic spaces



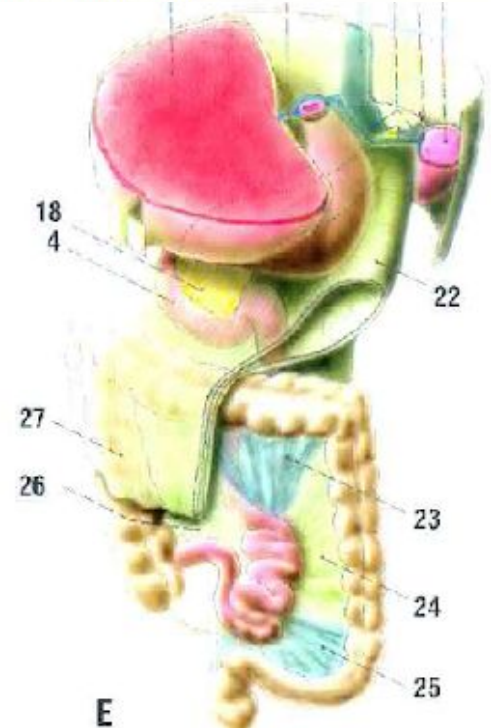
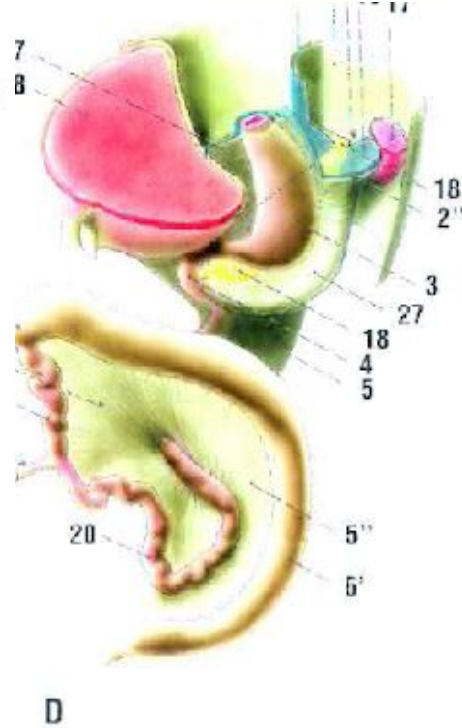
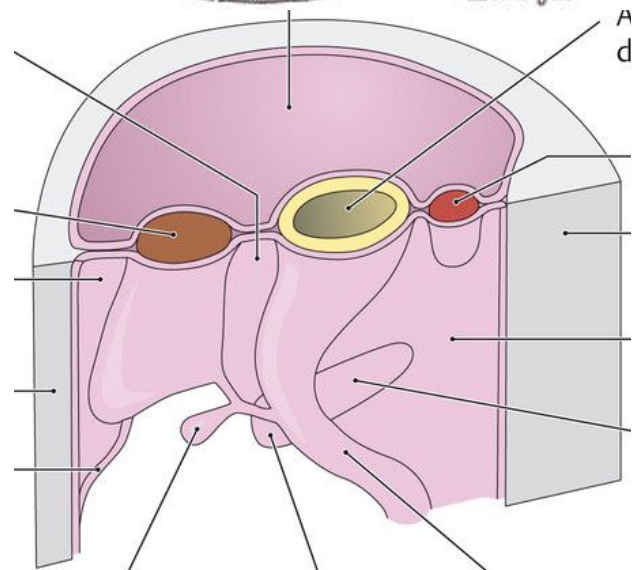
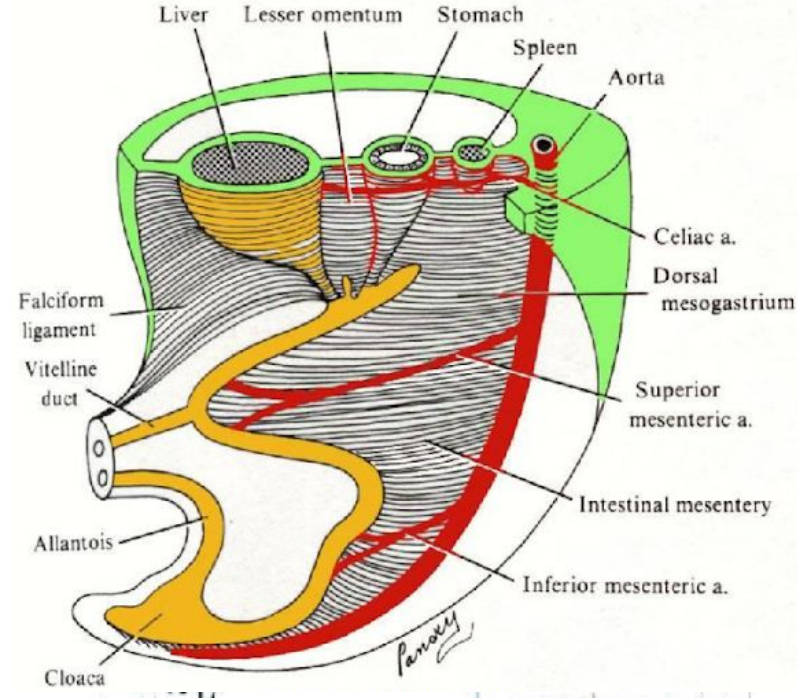
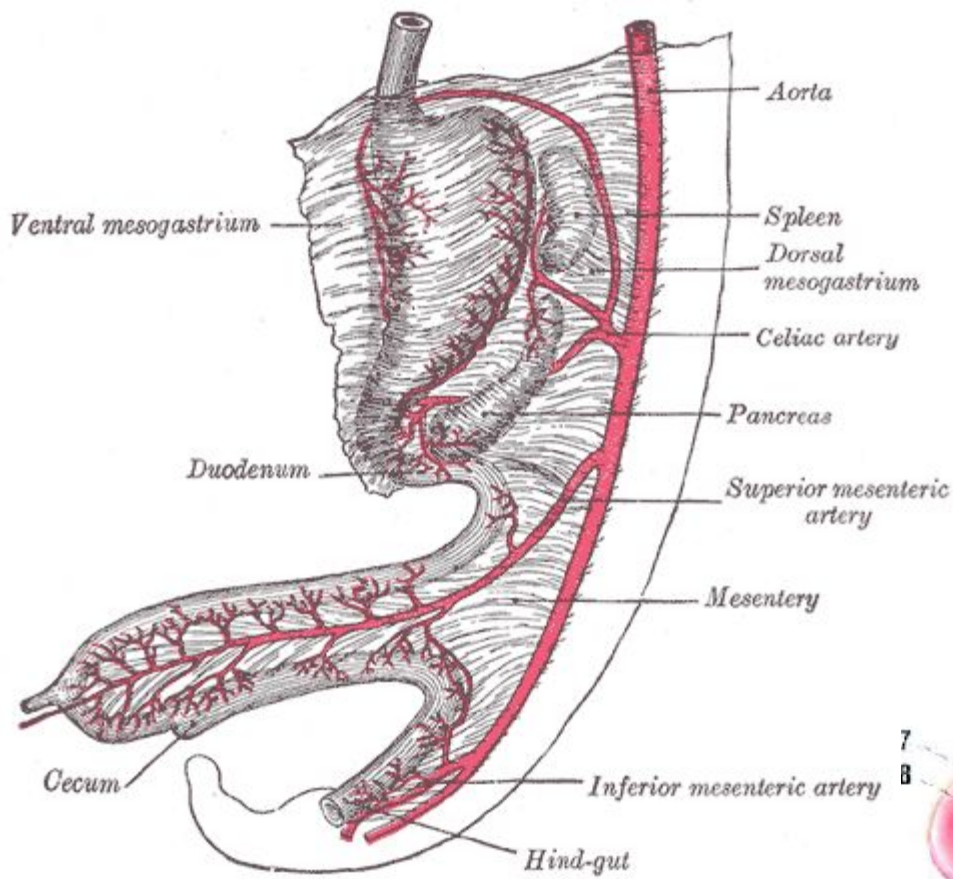
# PERITONEUM

- The abdominal cavity is lined with a shiny serous membrane – the peritoneum
- **In women, the abdominal cavity communicates with the outside** through the openings of the fallopian tubes
- Parietal and visceral peritoneum
  - serosa (mesothelium with tela subserosa)
- **mesenteria** = závěsy: dvojité listy pobřišnice, jimi přechází nástěnné peritoneum do viscerálního peritonea (vede cévy a nervy), má kořen = **radix**, kterým se připojuje na zadní stranu břišní stěny
- **mesenteries** = suspensory ligaments: double layers of peritoneum, through which the parietal peritoneum transitions into the visceral peritoneum (carries blood vessels and nerves), has a root = **radix**, which connects it to the back of the abdominal wall
- **cavitas peritonealis (pars supramesocolica et inframesocolica) et extraperitonealis (retro-, pre-, subperitoneale)**
  - organs in pars supramesocolica supplied by arteries from truncus coeliacus
  - organs in pars inframesocolica supplied by arteries from aa. mesentericae

# PERITONEUM – DEVELOPMENT

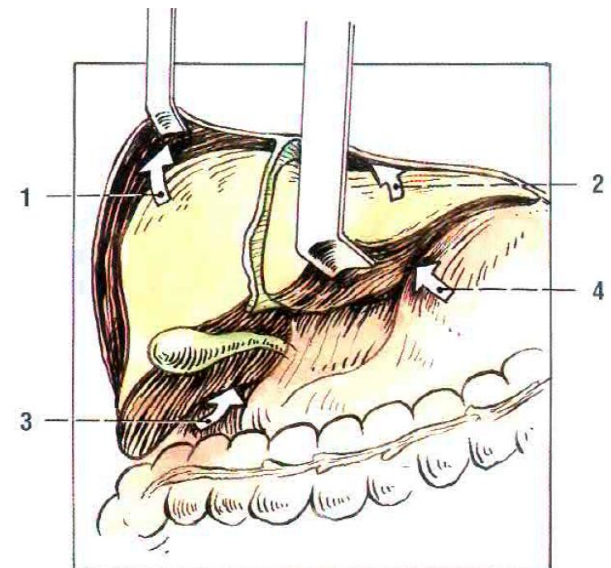
- the primitive digestive tract is connected to the abdominal wall via the dorsal mesentery and ventral mesentery (terminating in the umbilical vein)
- mesenterium dorsale
  - dorsal mesogastrium – spleen, gastro-splenic and phrenic-splenic ligaments, greater omentum, gastrocolic ligament
  - dorsal mesoduodenum – pancreas
  - mesenterium
  - mesocolon
- mesenterium ventrale
  - mesogastrium ventrale, mesoduodenum ventrale
  - the liver divides them into omentum minus (ligamentum hepatogastricum, ligamentum heptaoduodenale) and ligamentum falciforme hepatis
- with the rotation of the small intestine loops, the stomach and duodenum also turn
  - mesoduodenum adheres to the parietal peritoneum of the posterior wall (duodenum and pancreas are secondarily retroperitoneal)
  - the jejunioileum pulls the mesentery and pushes the colon to the sides (the originally free mesocolon ascendens and descendens adhere to the parietal peritoneum, the colon transversum retains the mesocolon transversum, the colon sigmoideum retains the mesocolon sigmoideum)

<https://www.youtube.com/watch?v=lySNeVVyaKQ>

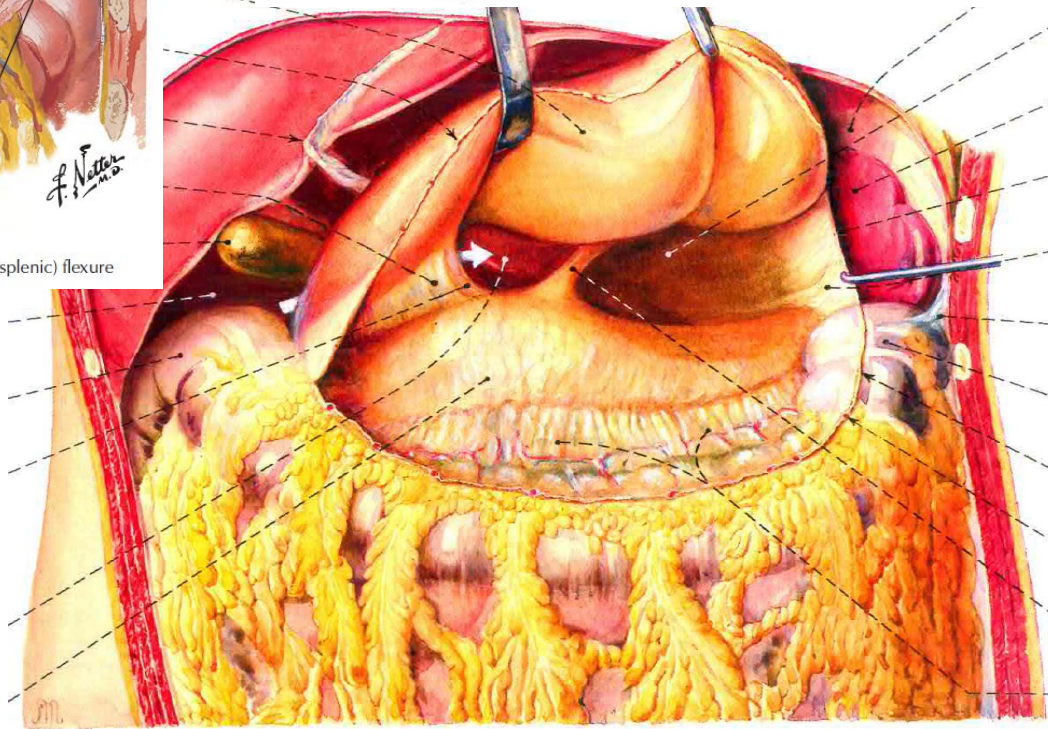
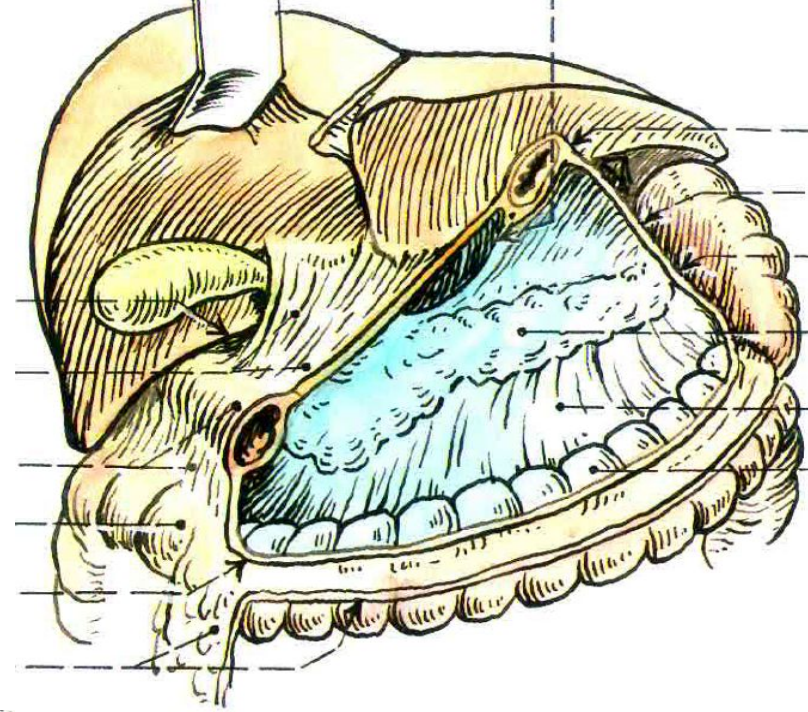
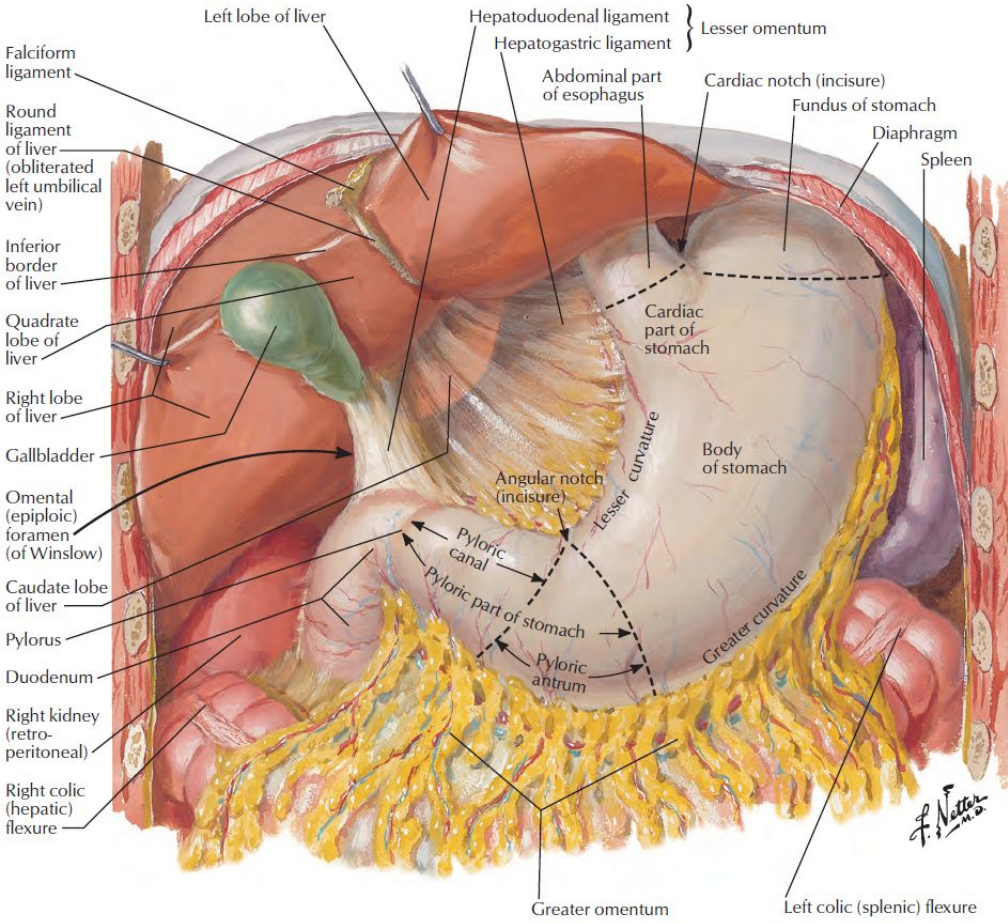


# PARS SUPRAMESOCOLICA

- above the radix mesocoli transversi
- organs are closely adjacent to each other (cavity = system of slits filled with a thin layer of peritoneal fluid)
- right: **recessus subphrenici** (right = 1 and left = 2) et **subhepatici** (right = 3 and left = 4)
- left: **saccus splenicus** – caudally terminated by lig. phrenicocolicum
- **bursa omentalis** – separate section of the peritoneal cavity behind the stomach
  - front: stomach and its suspensory ligaments (**omentum minus**, lig. gastrocolicum)
  - behind: parietal peritoneum in front of the duodenum and pancreas
  - above: liver and diaphragm
  - below: mesocolon transversum and colon transversum
  - left: hilum of the spleen, ligamentum phrenicosplenicum + ligamentum gastrophrenicum – continues as ligamentum gastrosplenicum – passes into ligamentum gastrocolicum
  - right: **foramen epiploicum** (foramen omentale) (Winslow) – in front **lig. hepatoduodenale**, behind lig. hepatorenale, below pars superior duodeni (or variable lig. duodenorenale)
  - plica hepatopancreatica (a. hepatica communis) and plica gastropancreatica (a. gastrica sin.)

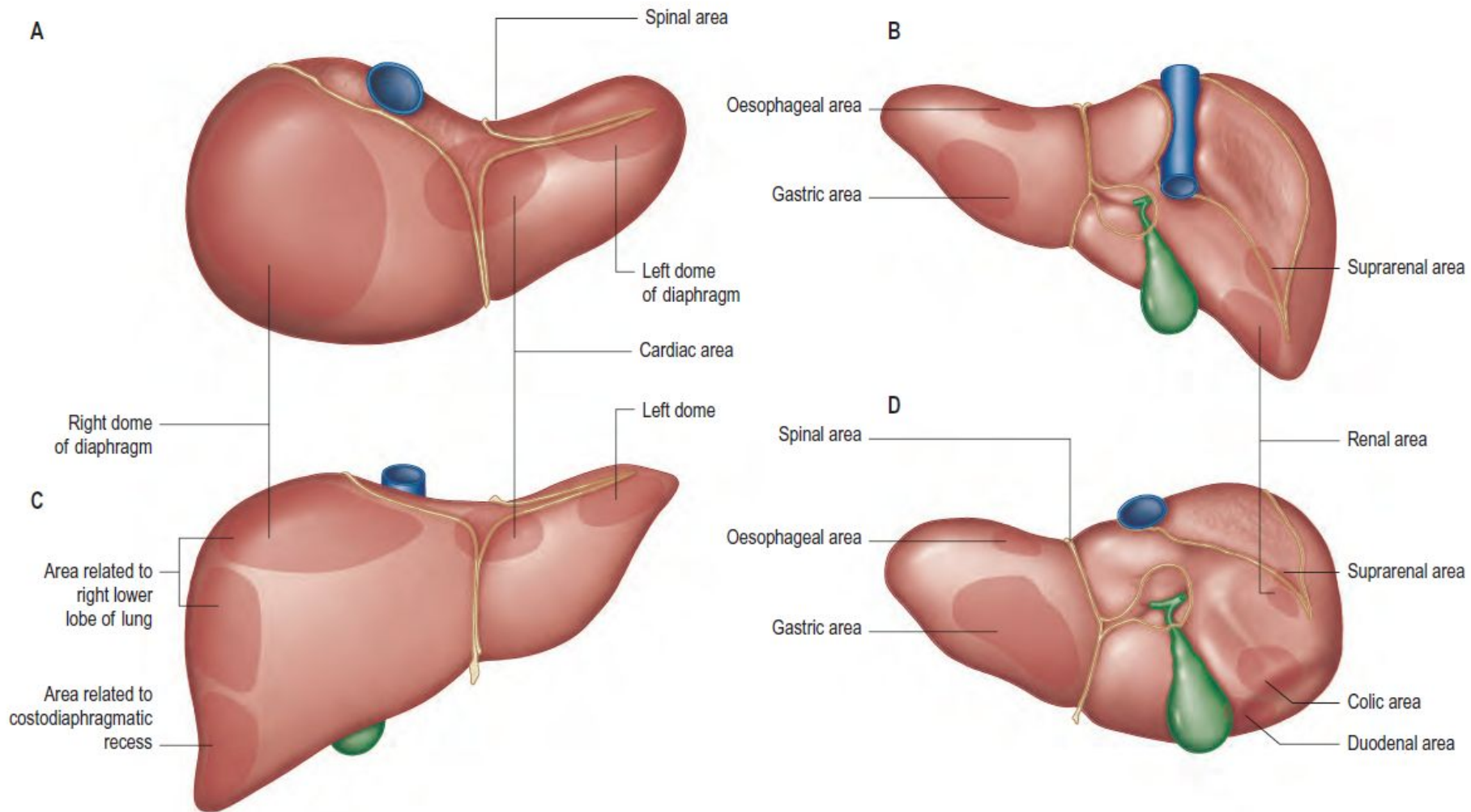


# BURSA OMENTALIS

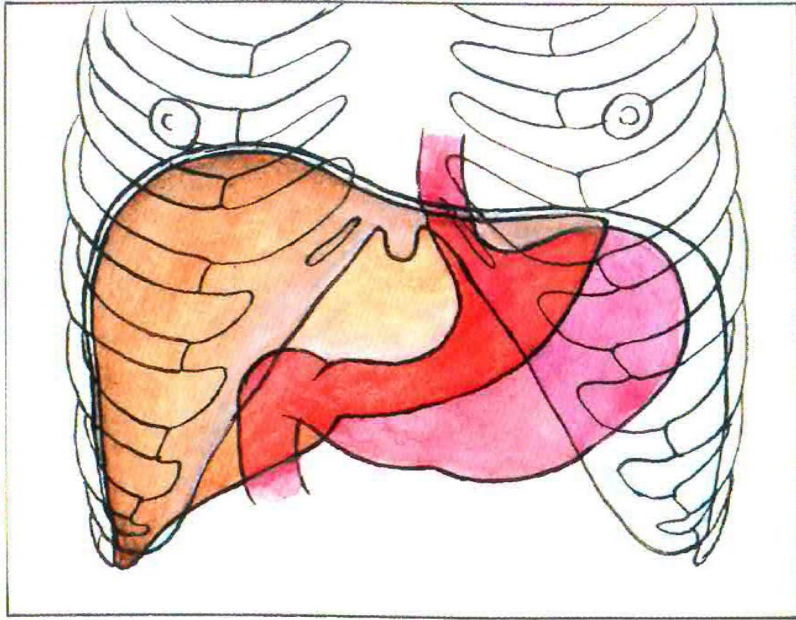


# PARS INFRAMESOCOLICA

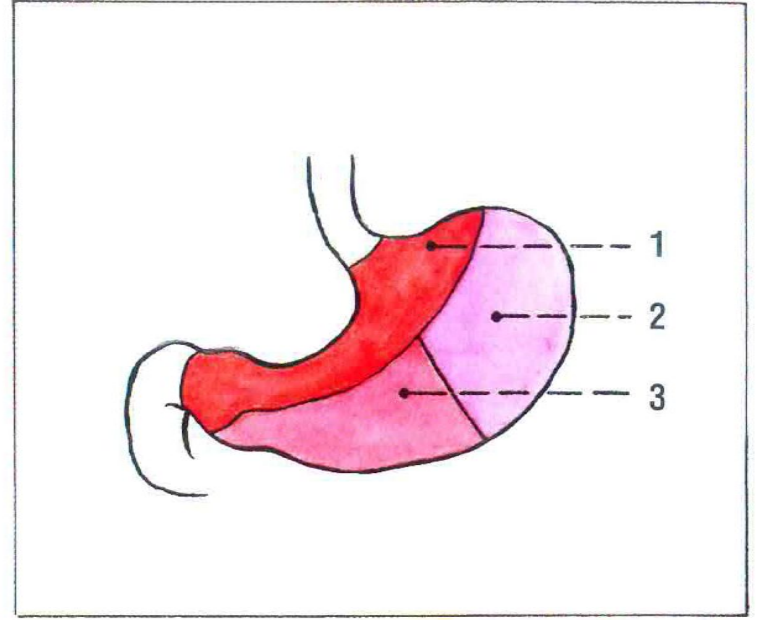
- under the radix mesocoli transversi
- radix mesenterii – diagonal division of the cavity into adhesion fields
- right infracolic compartment
  - arteries from the superior mesenteric artery and corresponding veins are visible
  - supply of organs from this artery
- left infracolic compartment
  - arteries from the inferior mesenteric artery and corresponding veins are visible
  - supply of organs from this artery
- secondary imperfect adhesions of the mesentery of the large intestine to the posterior wall of the peritoneal cavity leaves recessus, fossae et plicae in here
- flexura duodenojejunalis
  - ostium ileocaecale and caecum – recessus retrocaecalis (the appendix may be located here)
  - ascending colon
  - descending colon
  - mesocolon sigmoideum



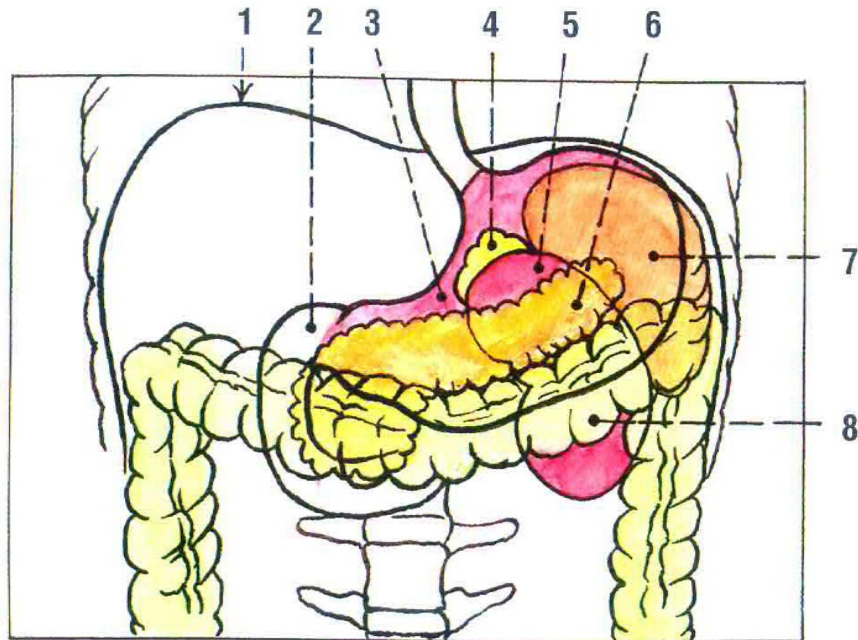
**Fig. 67.3** Relations of the liver. **A**, Superior view. **B**, Posterior view. **C**, Anterior view. **D**, Inferior view.



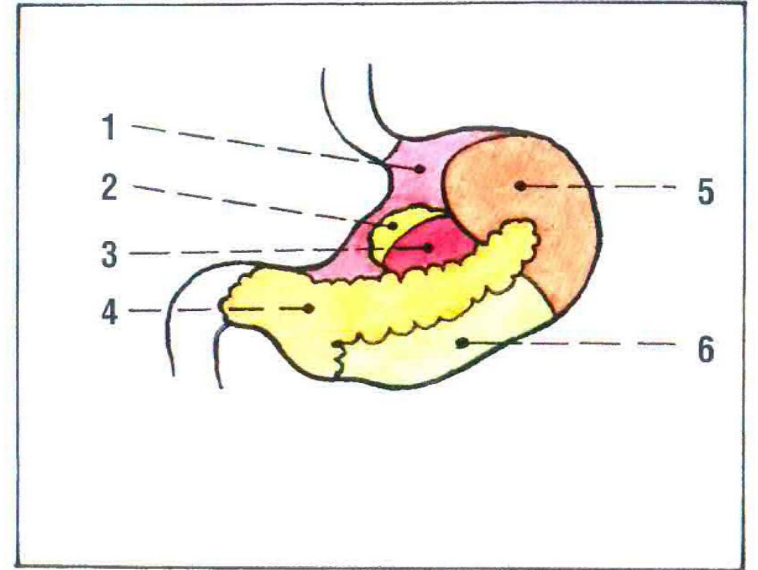
A



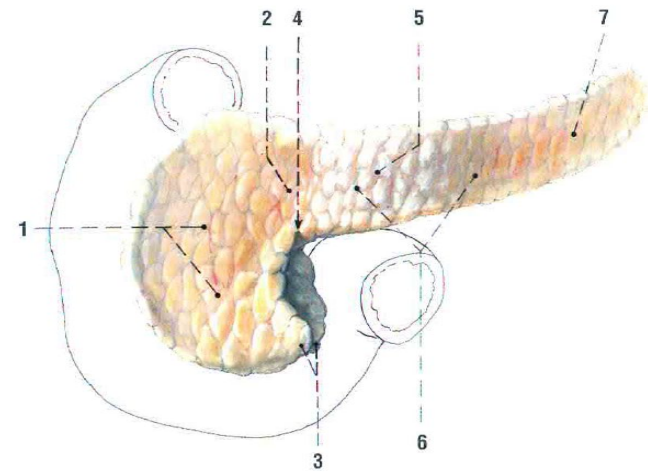
B



C



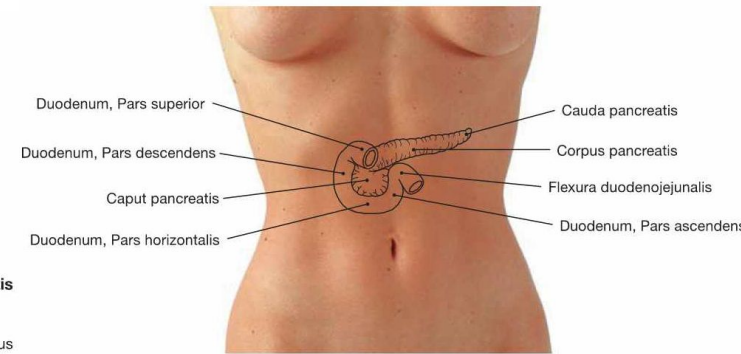
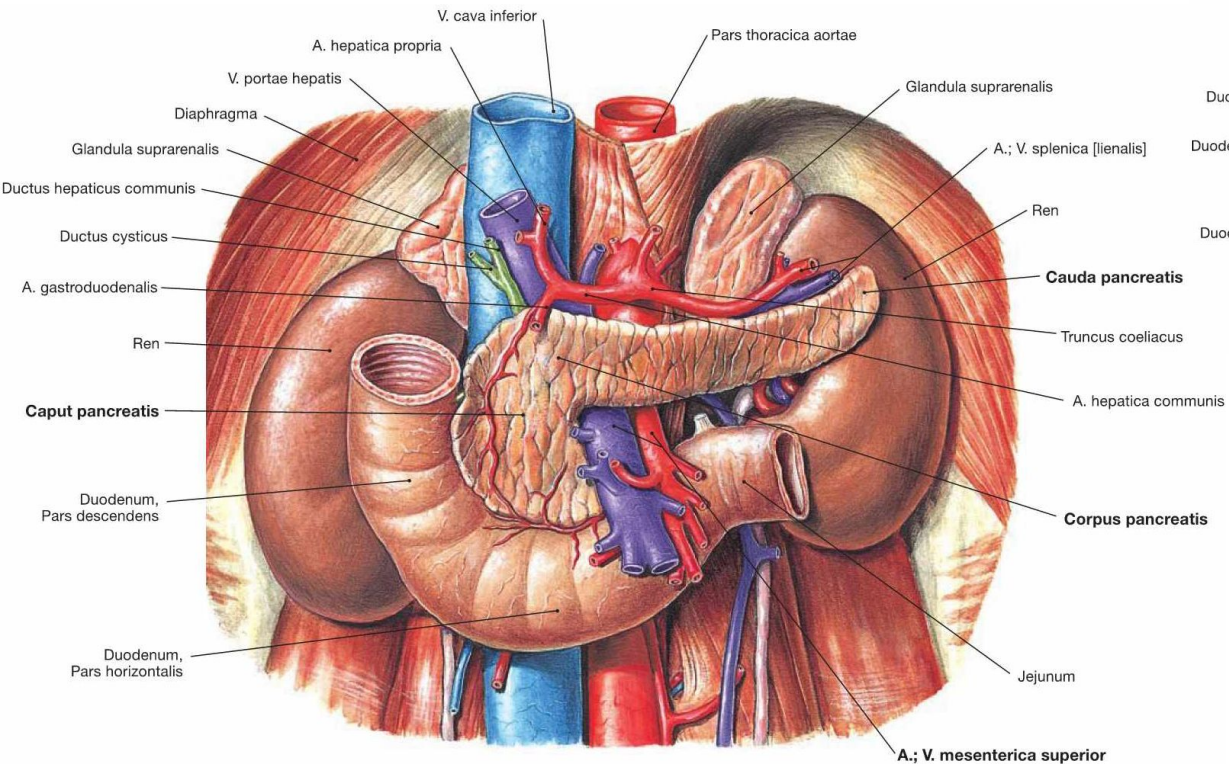
D



Obr. 89. PANCREAS; naznačen průběh duodena; pohled zředu

- 1 caput pancreatis
- 2 collum pancreatis
- 3 proc. uncinatus
- 4 incisura pancreatis

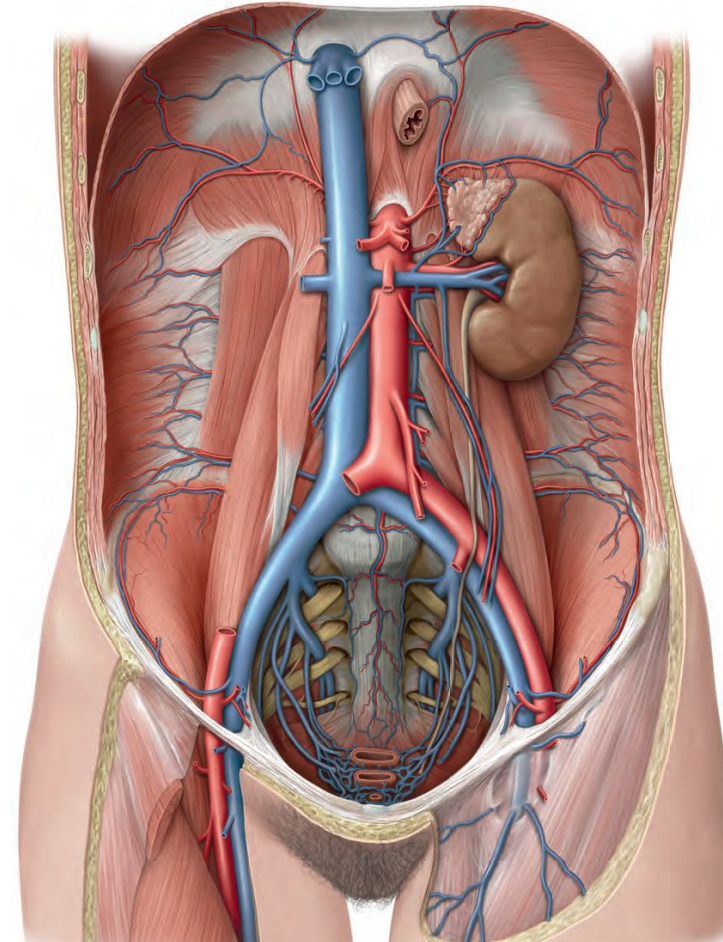
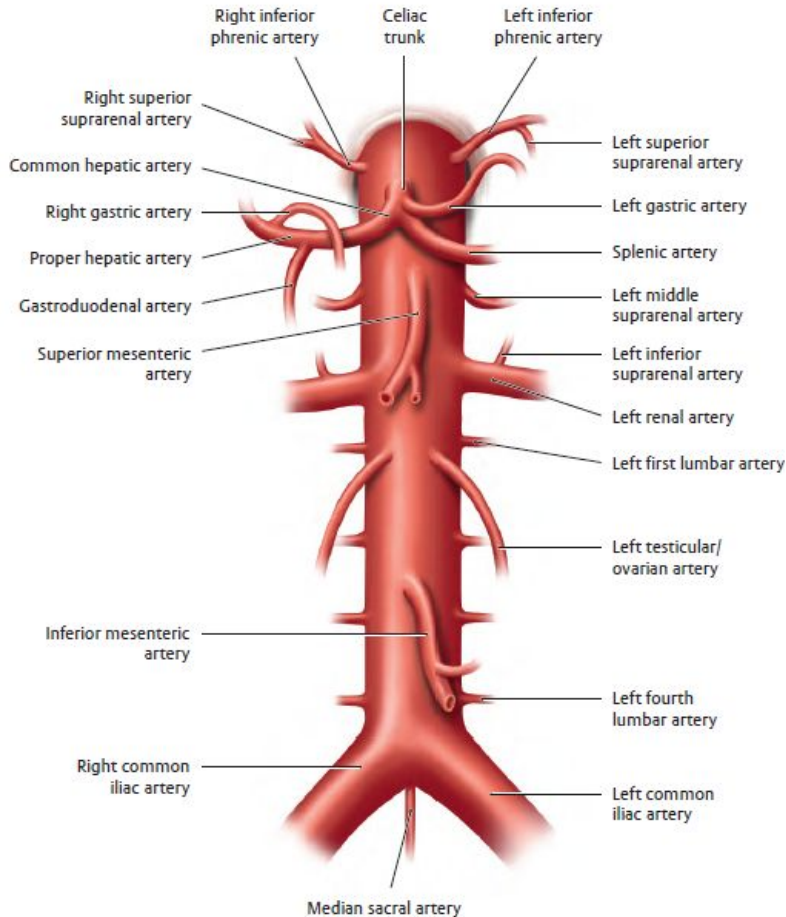
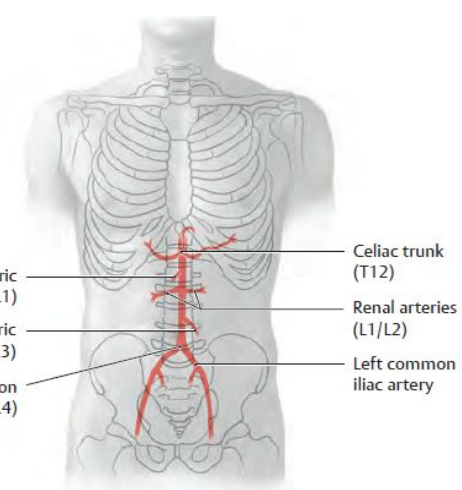
- 5 tuber omentale
- 6 corpus pancreatis
- 7 cauda pancreatis



# ABDOMINAL AORTA

- three unpaired visceral branches
  - celiac trunk (supramesocolic space)
  - superior mesenteric artery (right inframesocolic space)
  - inferior mesenteric artery (left inframesocolic space)
- three paired visceral branches
  - middle suprarenal artery, renal artery, gonadal artery
- "three" parietal branches
  - inferior phrenic artery, lumbar arteries, median sacral artery

anastomosis magna at the left colic flexure  
 middle rectal artery  
 +  
 left renal artery



# OVERVIEW OF THE ABDOMINAL ARTERIES I.

## parietal branches of the a. abdominis

- a. phrenica inferior
  - aa. suprarenales superiores
- aa. lumbales
  - in four pairs from the dorsolateral circumference, below the m. psoas major and m. quadratus lumborum
  - rr. dorsales et spinales (supplies the back muscles, skin of the back, vertebrae, spinal cord with its coverings)
- a. sacralis mediana
  - from the bifurcation of the aorta
  - at the tip of the coccyx, it ends in the glomus coccygeum (arteriovenous anastomosis)

## visceral branches a. abdominis – paired

- a. suprarenalis media
- a. renalis
  - intervertebral disc L1–L2
  - on the right behind the inferior vena cava, on the left behind the renal vein sin.
  - inferior suprarenal artery
- testicular artery (ovarian artery)
  - obliquely along m. psoas major
  - at the transition to the pelvis, it crosses the ureter and a. iliaca externa
  - a. testicularis goes into the inguinal canal and into the spermatic cord to the testicle and epididymis
  - a. ovarica into the lig. suspensorium ovarii and into the hilum of the ovary

# OVERVIEW OF THE ABDOMINAL ARTERIES II.

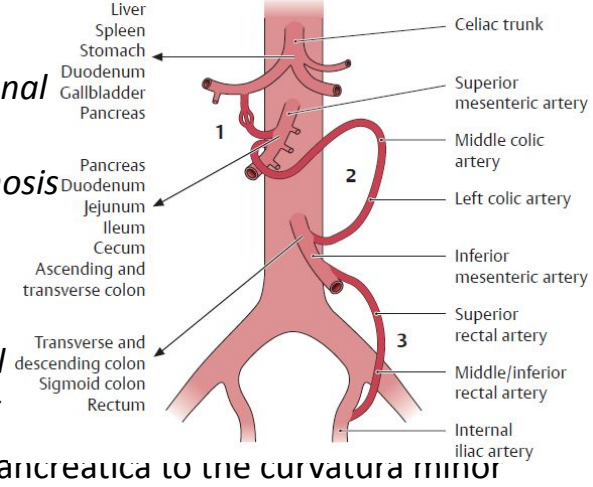
visceral branches of the a. abdominis – unpaired

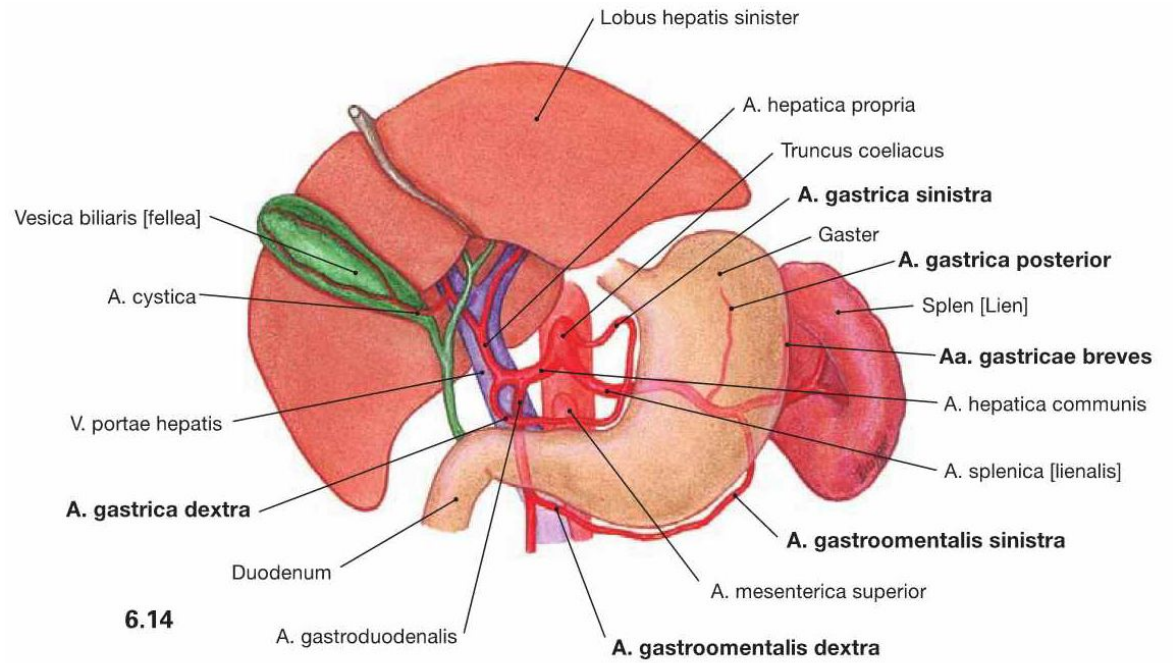
- coeliac trunk
  - originates at the level of Th12–L1
  - supplies all organs in the supramesocolic part of the peritoneal cavity
  - branches: a. gastrica sinistra, a. hepatica communis, a. lienalis
- left gastric artery
  - to the left along the posterior wall of the bursa omentalis in the plica gastropancreatica to the curvatura minor ventriculi
  - rr. oesophagei
- common hepatic artery
  - along the upper edge of the pancreas to the right to the pylorus, where it branches
  - proper hepatic artery – in lig. hepatoduodenale to the liver (on the right ductus choledochus, behind v. portae), gives off a. gastrica dx. (anastomosis with a. gastrica sin.), in porta hepatis it divides into ramus dx. et sin., most often from r. dx. a. cystica
  - gastroduodenal artery – caudally behind the pylorus, branches:
    - a. gastroepiploica dextra – along the curvatura major ventriculi, anastomosis with a. gastroepiploica sin. (branch of a. lienalis)
    - a. pancreaticoduodenalis superior – between the duodenum and caput pancreatis, r. posterior et anterior – connections with a. pancreaticoduodenalis inferior (branch of a. mesenterica superior)
- a. lienalis (splenica)
  - strongest branch of the coeliac trunk
  - waves along the upper edge of the pancreas on the posterior wall of the omental bursa to the hilum of the spleen (plica pancreaticolienalis)
  - a. gastroepiploica sinistra (plica gastrolienalis)
  - rr. pancreatici
  - aa. gastricae breves

## 1. pancreaticoduodenal arteries

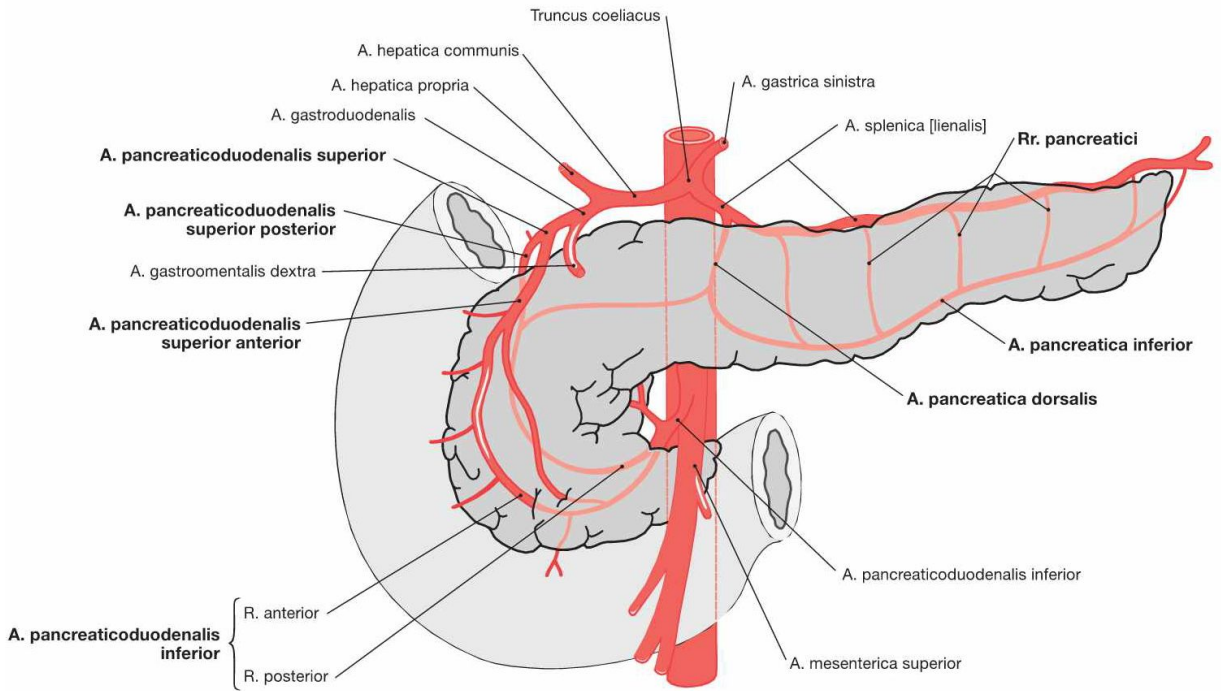
## 2. anastomosis magna

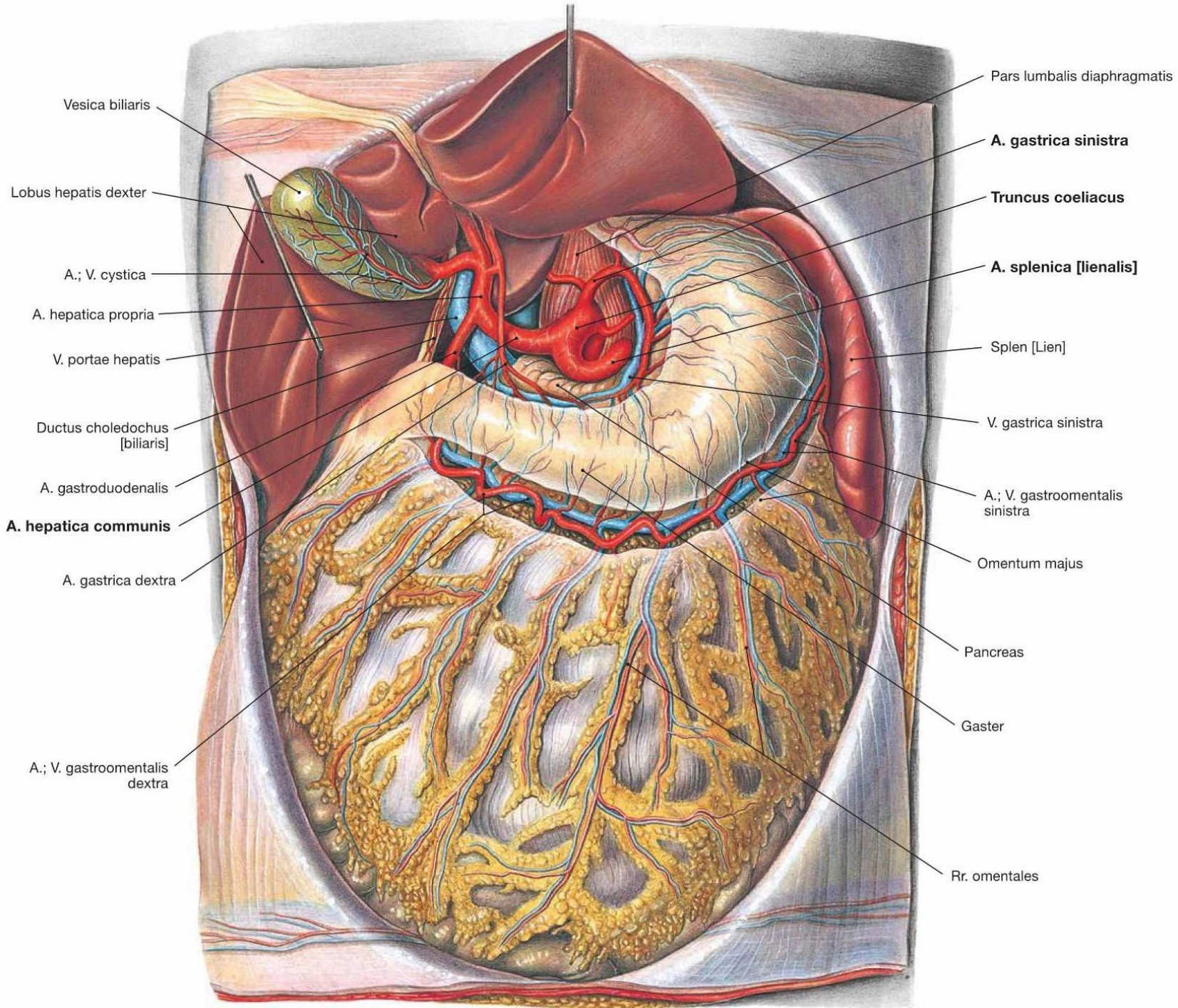
## 3. rectal arteries





6.14





# OVERVIEW OF THE ABDOMINAL ARTERIES III.

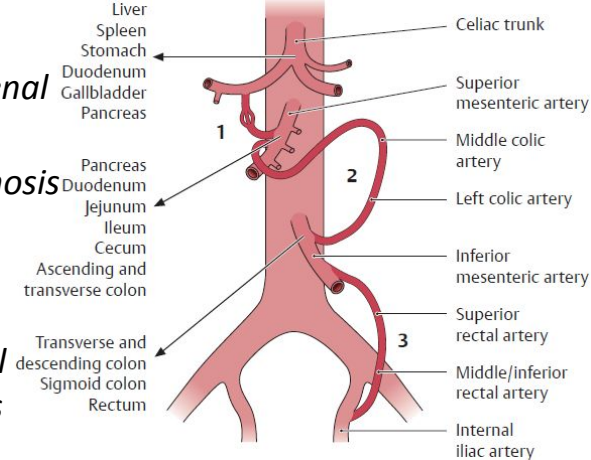
visceral branches of the a. abdominis – unpaired

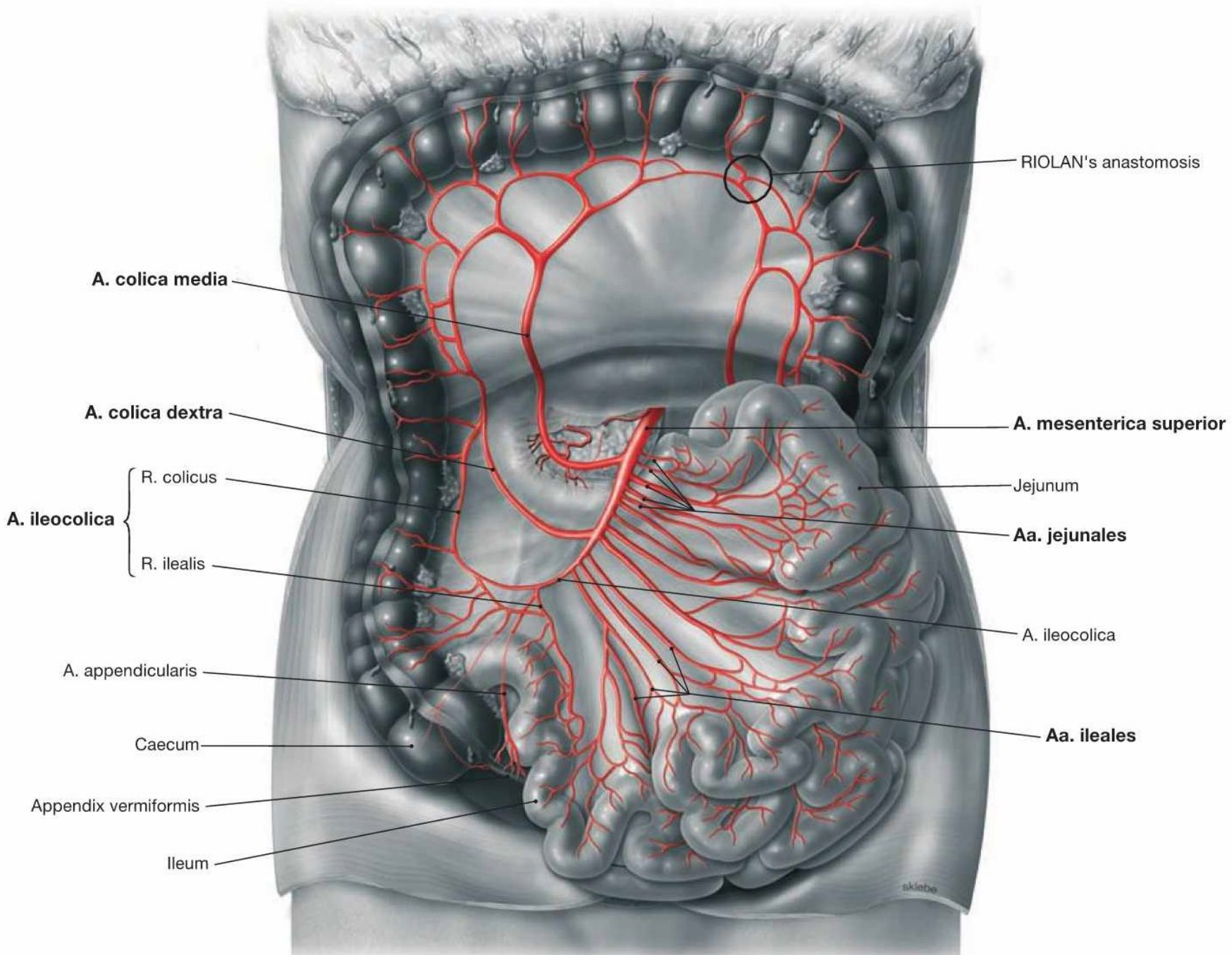
- superior mesenteric artery
  - supplies the small intestine and organs in the right infrasplic field in the right infrasplic part of the peritoneal cavity and the infrasplic part of the pancreas and duodenum
  - emerges behind the body of the pancreas and continues caudally in front of the processus uncinatus and in front of the pars horizontalis (inferior) duodeni
  - enters the radix mesenterii
  - a. pancreaticoduodenalis inferior – r. posterior et anterior, anast. with a. pancreaticoduodenalis superior (branch of a. gastroduodenalis)
  - aa. jejunales et ilei – 12–16 arteries, anastomotic arches, arteriolae rectae
  - a. ileocolica – a. appendicularis
  - a. colica dextra – via the right ureter and m. psoas major to the colon ascendes and flexura coli dextra, anastomotic with a. ileocolica and a. colica media
  - a. colica media – to mesocolon transversum, at flexura coli sinistra anastomoses with a. colica sinistra (branch of a. mesenterica inferior) = anastomosis magna (Halleri, Riolani)
- inferior mesenteric artery
  - branches at the level of L3
  - supplies the left third of the transverse colon, descending colon, sigmoid colon, and upper part of the rectum
  - a. colica sinistra – ascending branch (anastomosis magna), descending branch (anastomosis with aa. sigmoideae)
  - aa. sigmoideae – several branches, upper artery anastomoses with a. colica sin., lower artery anastomoses with a. rectalis superior (Sudeck's anastomosis)
  - a. rectalis superior – several branches on the sides of the rectum, anast. with paired a. rectalis media et inferior (branches of a. iliaca interna, resp. a. pudenda interna)

1. *pancreaticoduodenal arteries*

2. *anastomosis magna*

3. *rectal arteries*





RIOLAN's anastomosis

A. colica media

A. colica dextra

A. ileocolica

R. colicus

R. ilealis

A. appendicularis

Caecum

Appendix vermiformis

Ileum

A. mesenterica superior

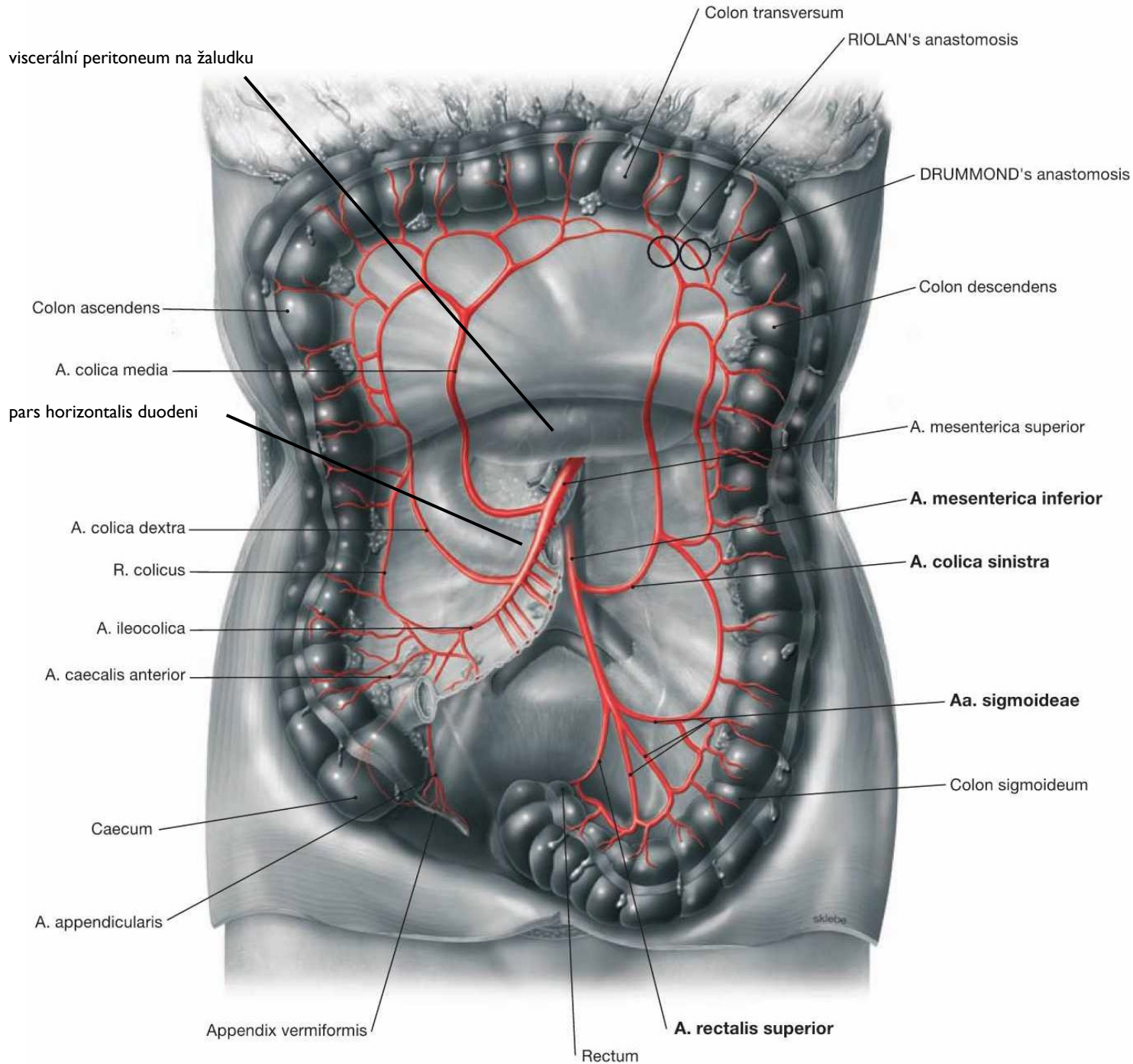
Jejunum

Aa. jejunales

A. ileocolica

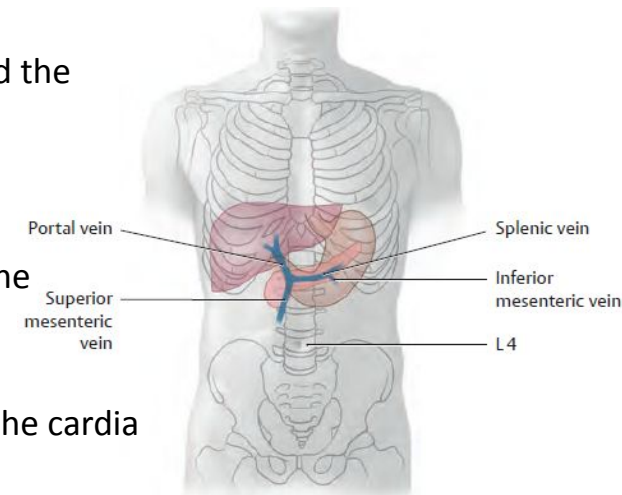
Aa. ileales

skebe

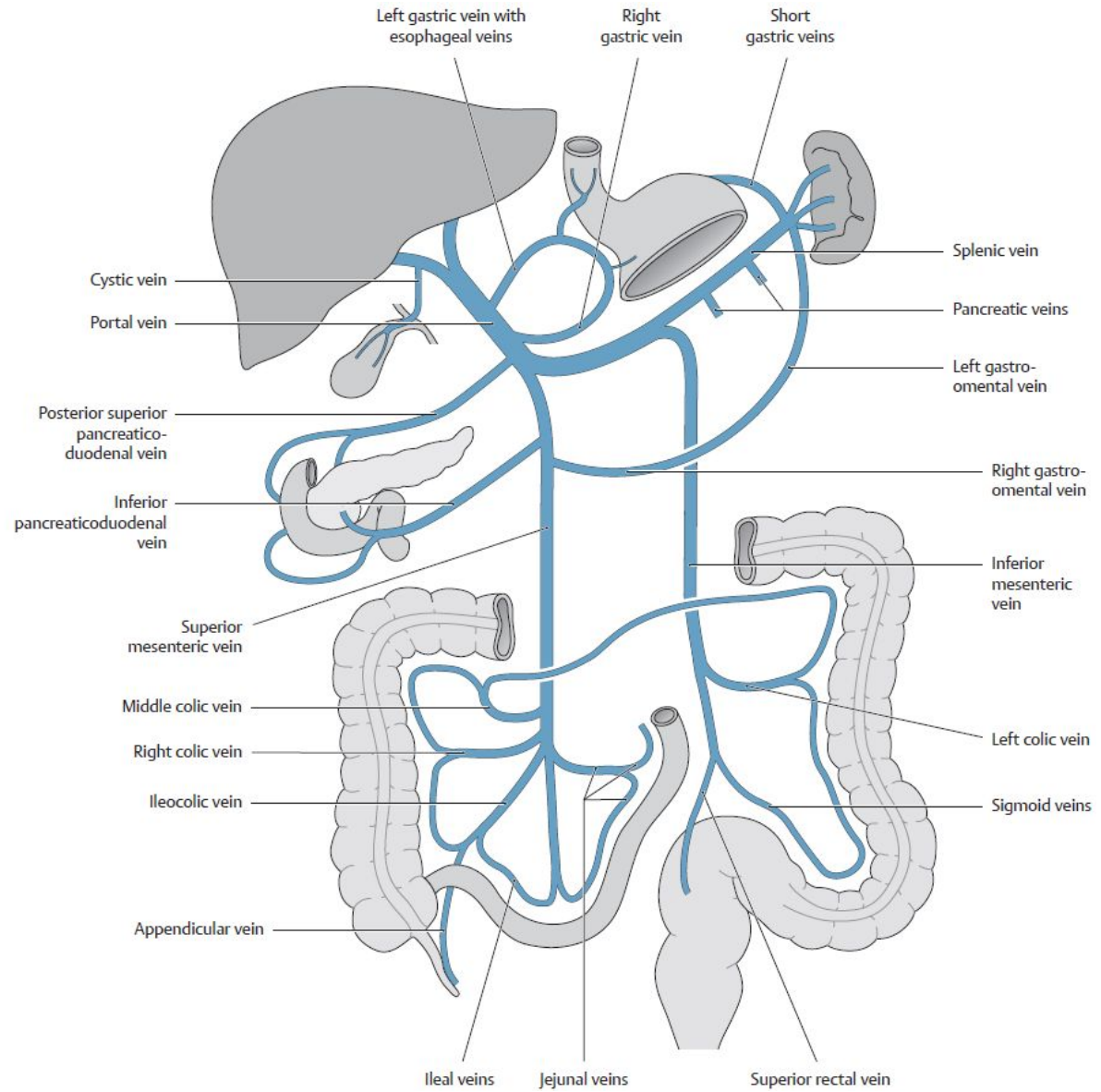
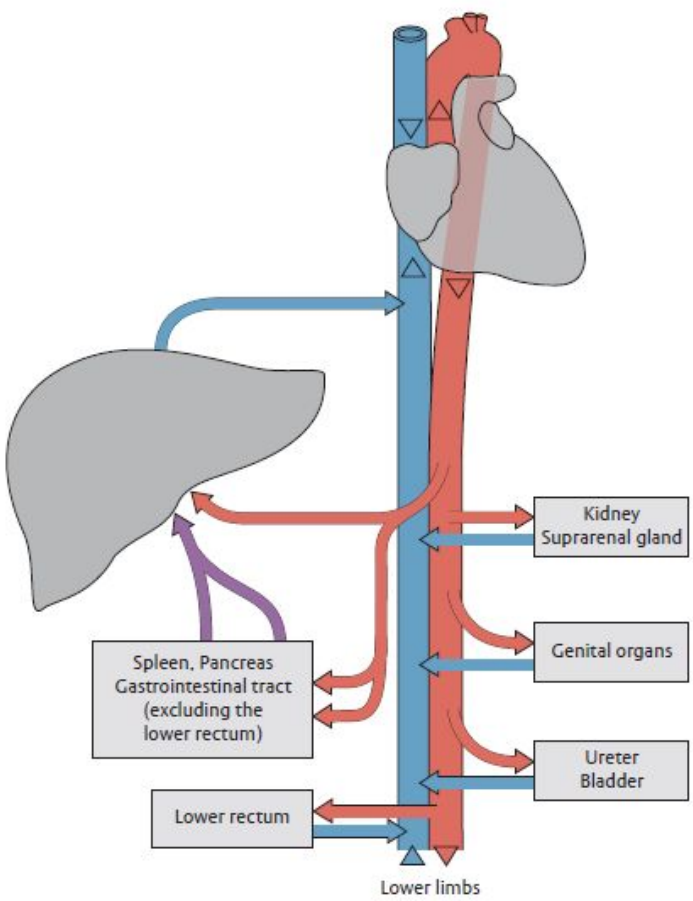


# PORTAL VENOUS SYSTEM

- blood from the veins of the unpaired organs of the abdominal cavity to the liver
- in the porta hepatis, it divides into the right and left branches
- it begins behind the head of the pancreas with the confluence (90°) of the superior mesenteric vein and the splenic vein (L2)
- rises behind the pars superior duodena dorsally from the gastroduodenal artery and the common bile duct
- enters the hepatoduodenal ligament (runs behind the common hepatic artery and the common bile duct)
- cystic vein, paraumbilical veins
- right gastric vein
  - blood from the right half of the lesser curvature of the stomach and from the pylorus
- left gastric vein
  - blood from the venous plexuses in the lower third of the esophagus, from the cardia and from the left half of the curv. minor ventriculi
- superior mesenteric vein
  - comes from the radix mesenterii through the pars horizontalis duodeni behind the head of the pancreas
  - in the mesentery, it is to the right of the a. mes. sup.
  - vv. pancreaticoduodenales, vv. pancreaticae, v. gastroepiploica dx., vv. jejunales et ileales, v. ileocolica, v. appendicularis, v. colica dx., v. colica media
- splenic vein
  - formed by the confluence of several branches in the hilum of the spleen and passes behind the pancreas
  - vv. gastricae breves, vv. pancreaticae, v. gastroepiploica sin.
  - inferior mesenteric vein (may flow into the confluence of v. lienalis and v. mes. sup.), confluence of v. colica sin., vv. sigmoideae, v. rectalis superior



# PORTAL VENOUS SYSTEM



# PORTOCAVAL ANASTOMOSES

① Through veins of the stomach and distal esophagus (dilation of these veins may lead to esophageal varices, with risk of life-threatening hemorrhage):

**Portal vein** ← gastric veins ← *esophageal veins* → azygos/hemiazygos vein → **superior vena cava**.

② Through veins of the anterior abdominal wall:

**Portal vein** ← umbilical vein (patent part) ← *paraumbilical veins* → periumbilical veins → superior epigastric vein → internal thoracic vein → subclavian vein → **superior vena cava** or

**Portal vein** ← umbilical vein (patent part) → *paraumbilical veins* → periumbilical veins → inferior epigastric vein → external iliac vein → **inferior vena cava**.

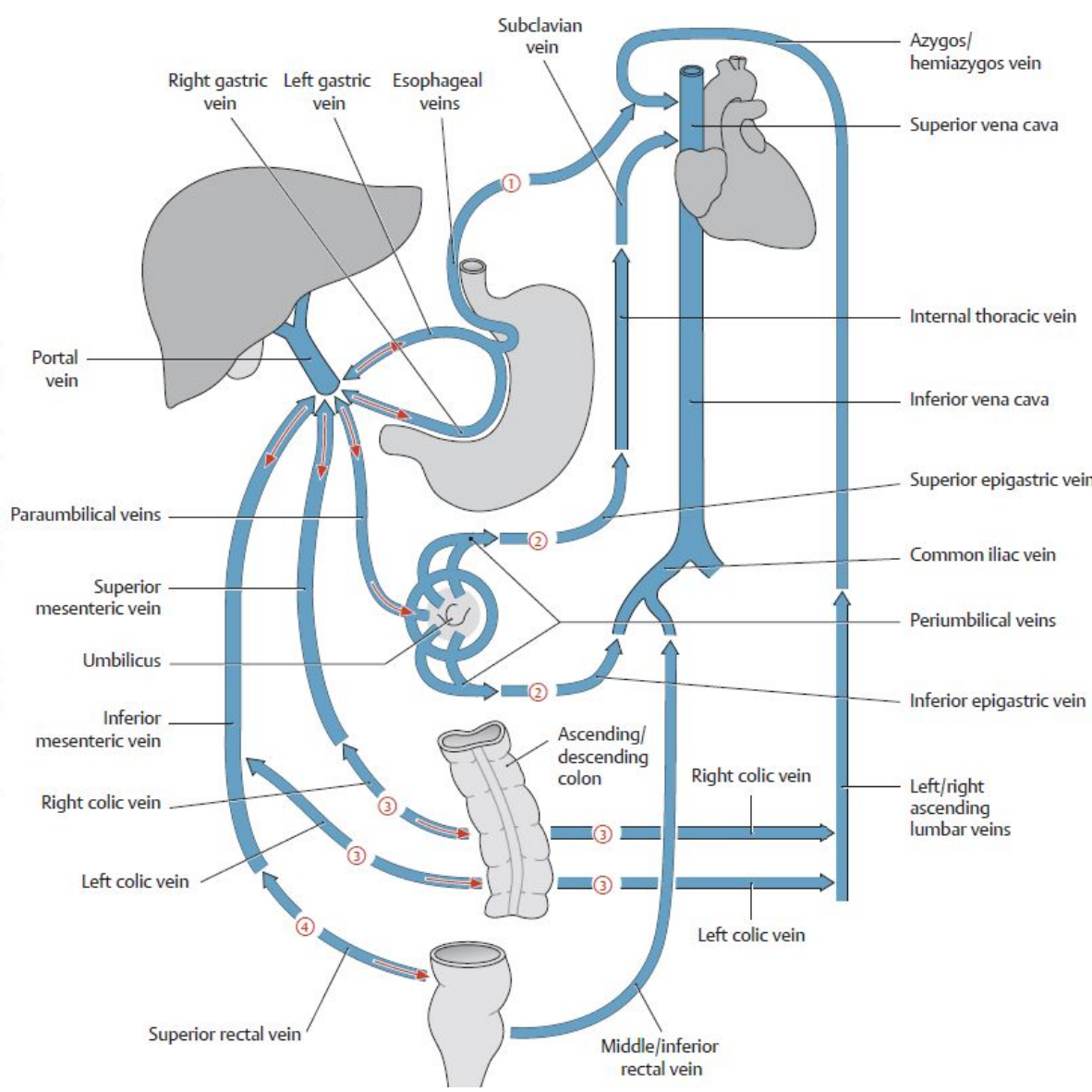
Note: Drainage from paraumbilical veins into the superficial veins (rare) of the anterior abdominal wall (thoracoepigastric vein, lateral thoracic vein, superficial epigastric vein, see A) leads to dilation of these tortuous veins (Medusa head, caput medusae).

③ Through veins of the posterior abdominal wall:

**Portal vein** ← superior and inferior mesenteric vein ← left and right *colic veins* → left and right ascending lumbar veins → azygos/hemiazygos vein → **superior vena cava**. The ascending lumbar veins may also divert blood to the inferior vena cava.

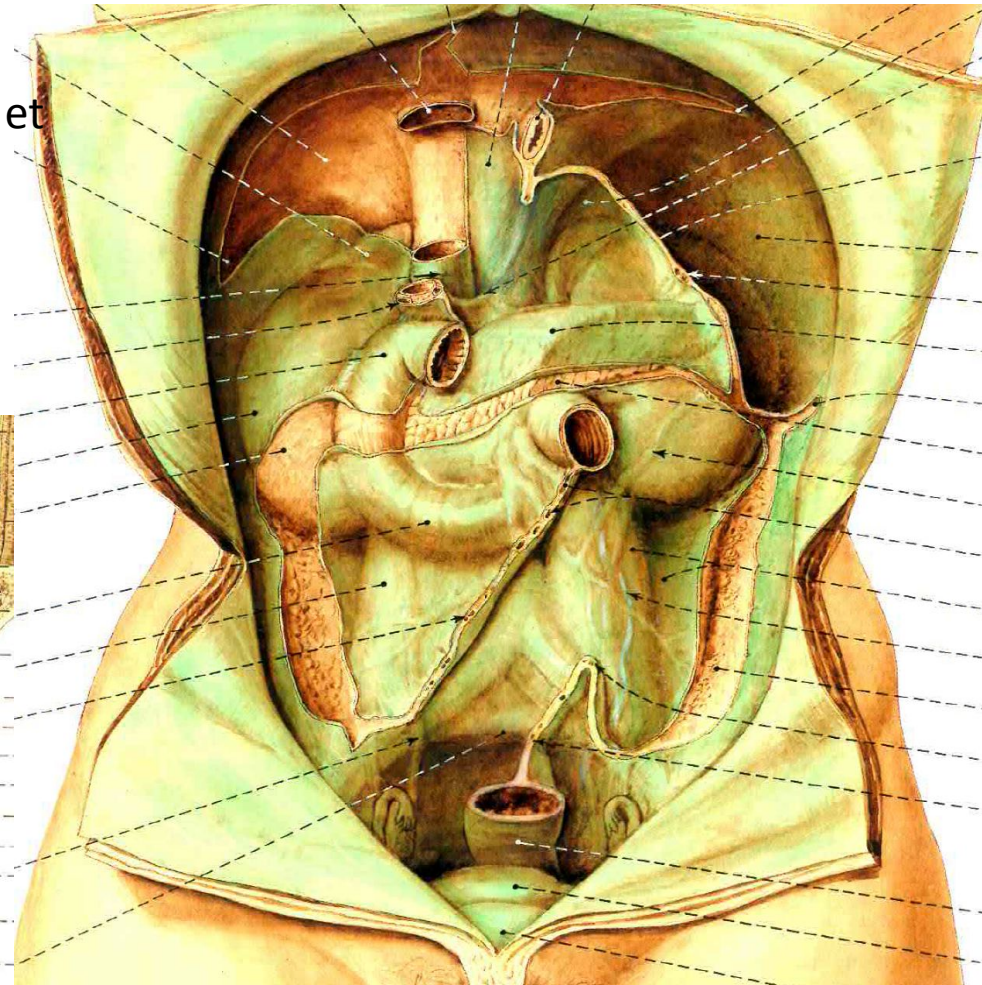
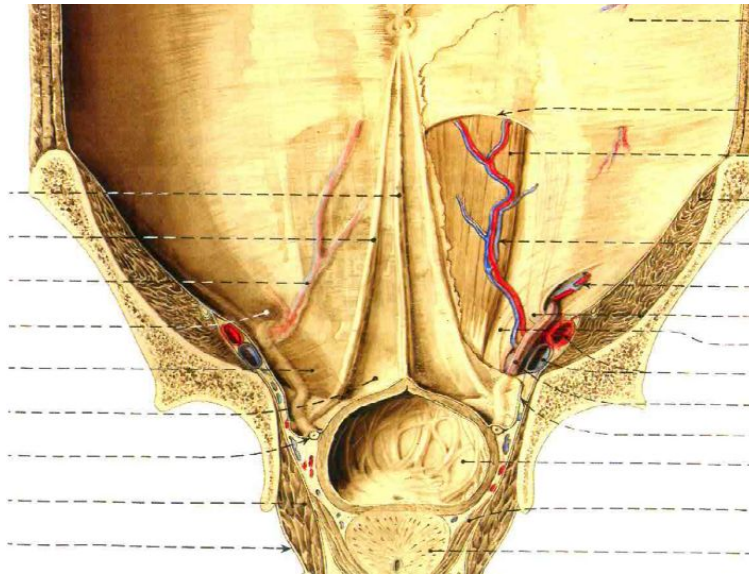
④ Through the rectal venous plexus (with dilation):

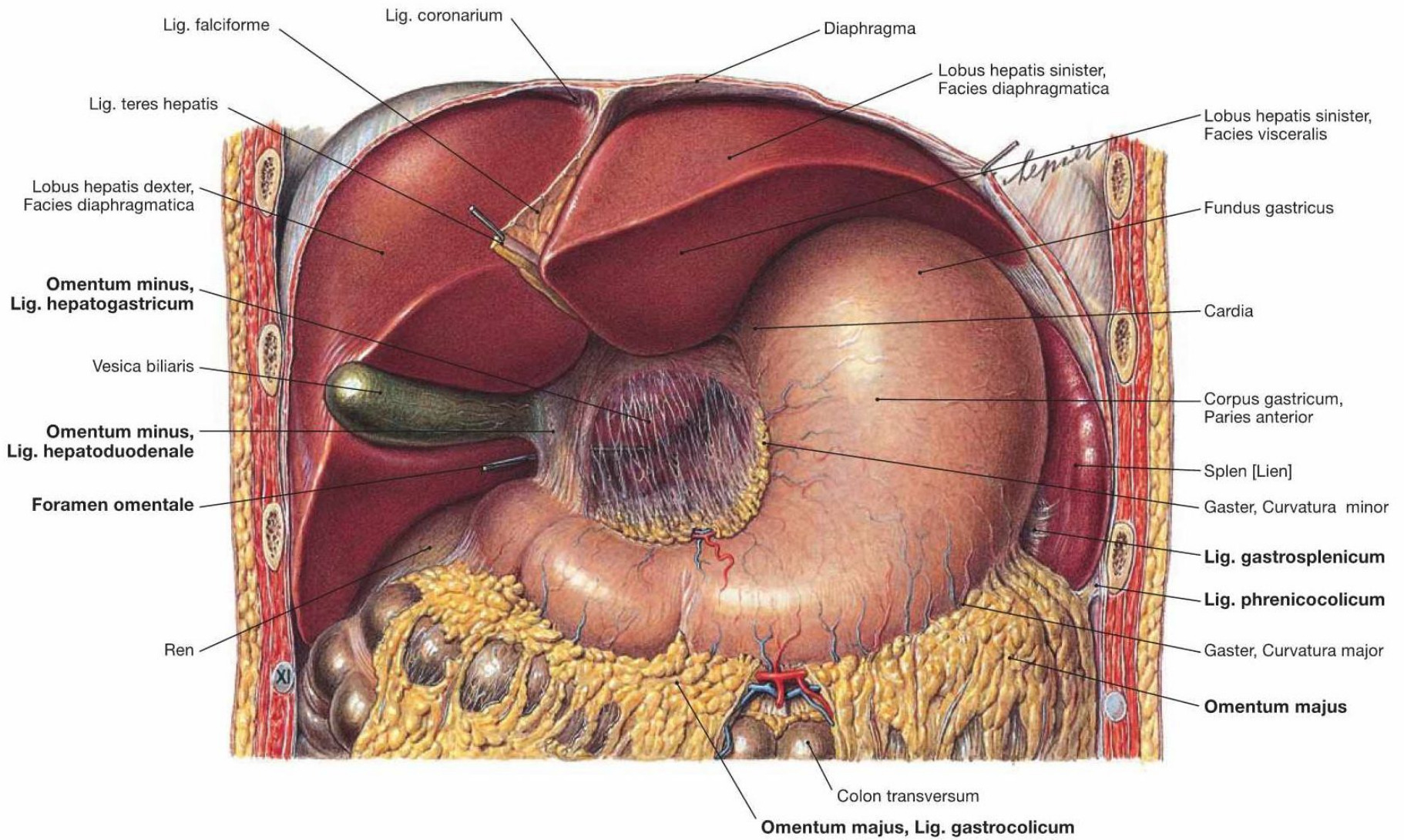
**Portal vein** ← inferior mesenteric vein ← superior rectal vein ← middle/*inferior rectal veins* → internal iliac vein → **inferior vena cava**.

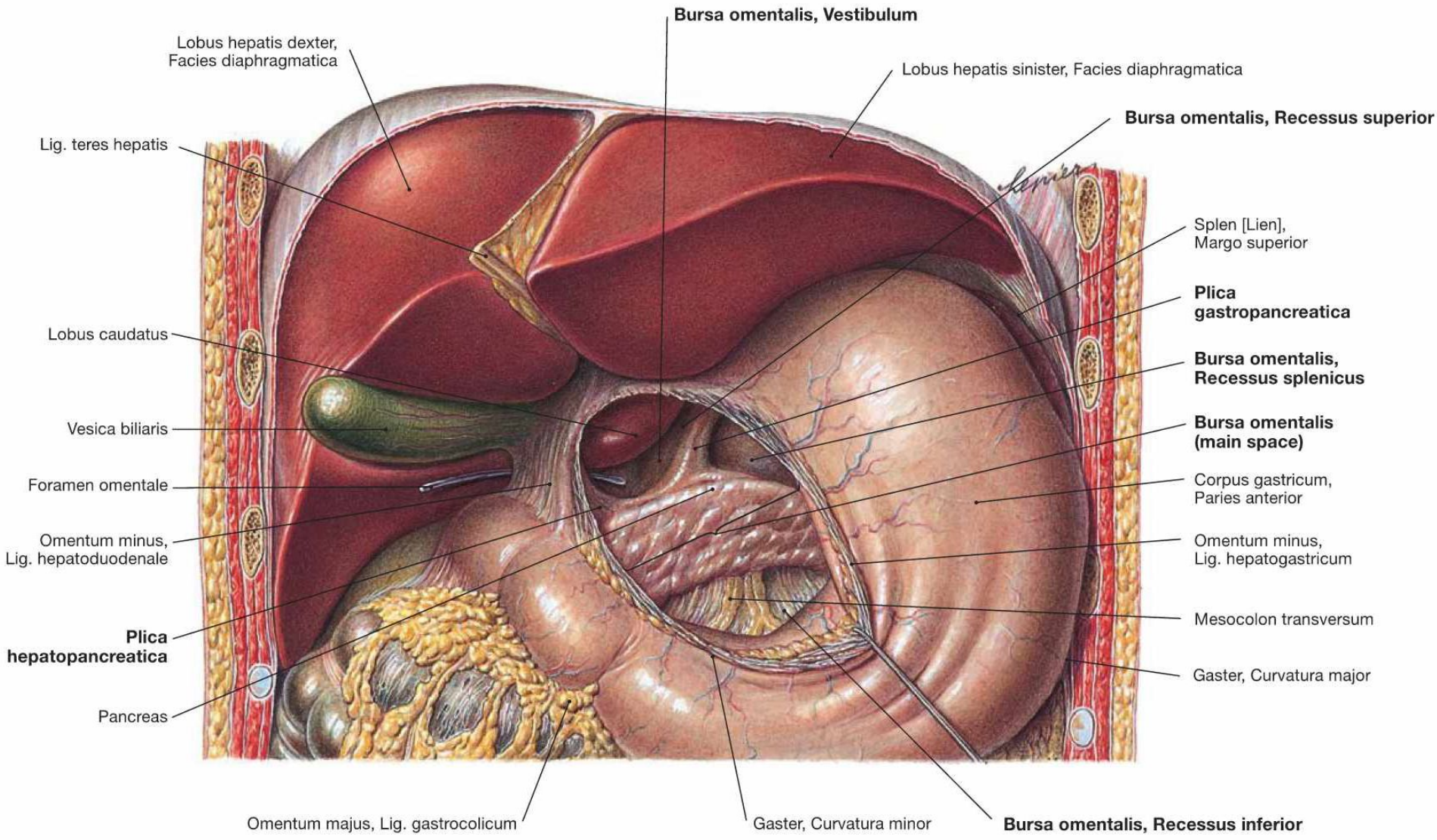


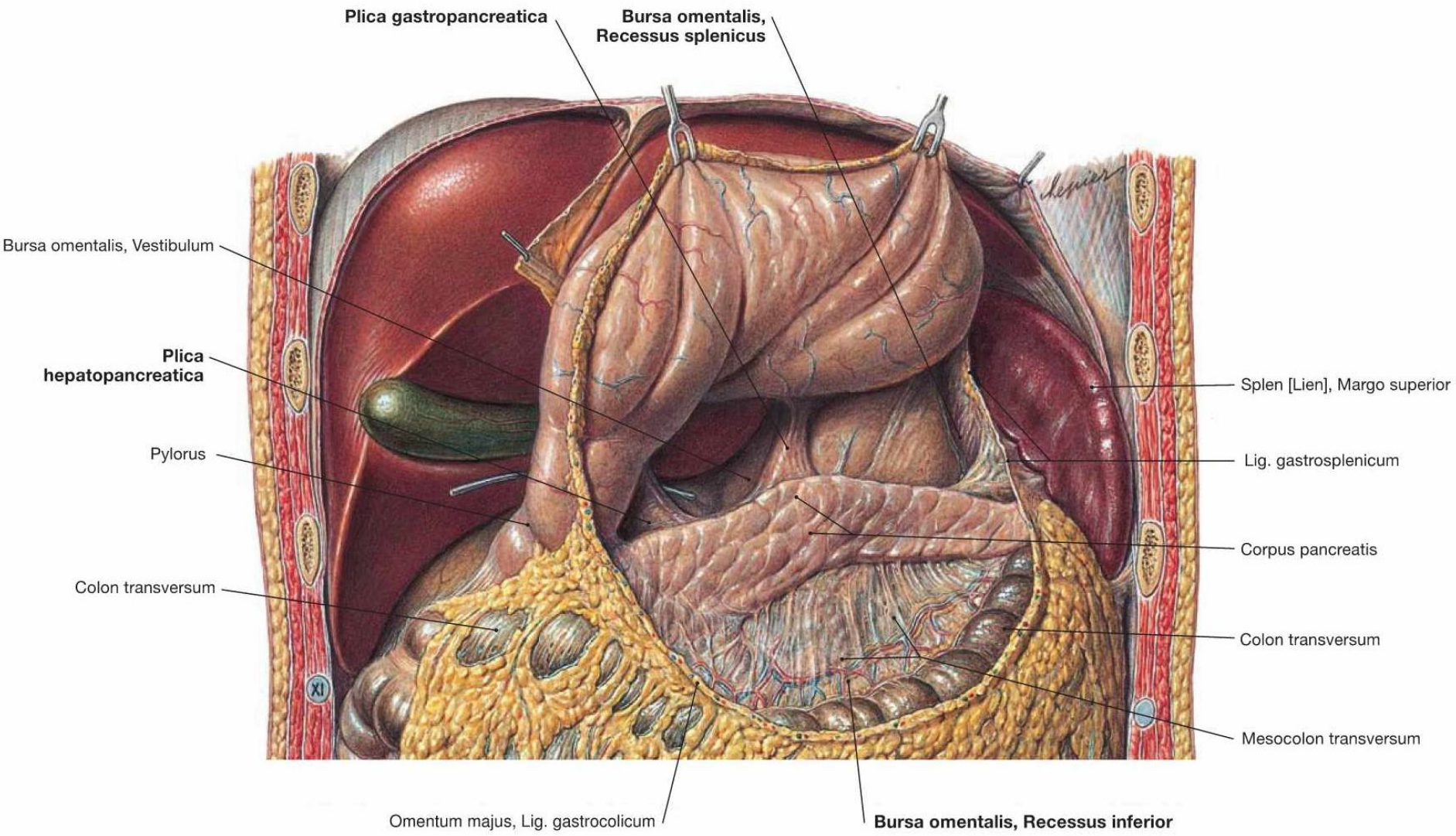
# PERITONEUM in the pelvis and on the anterior abdominal wall

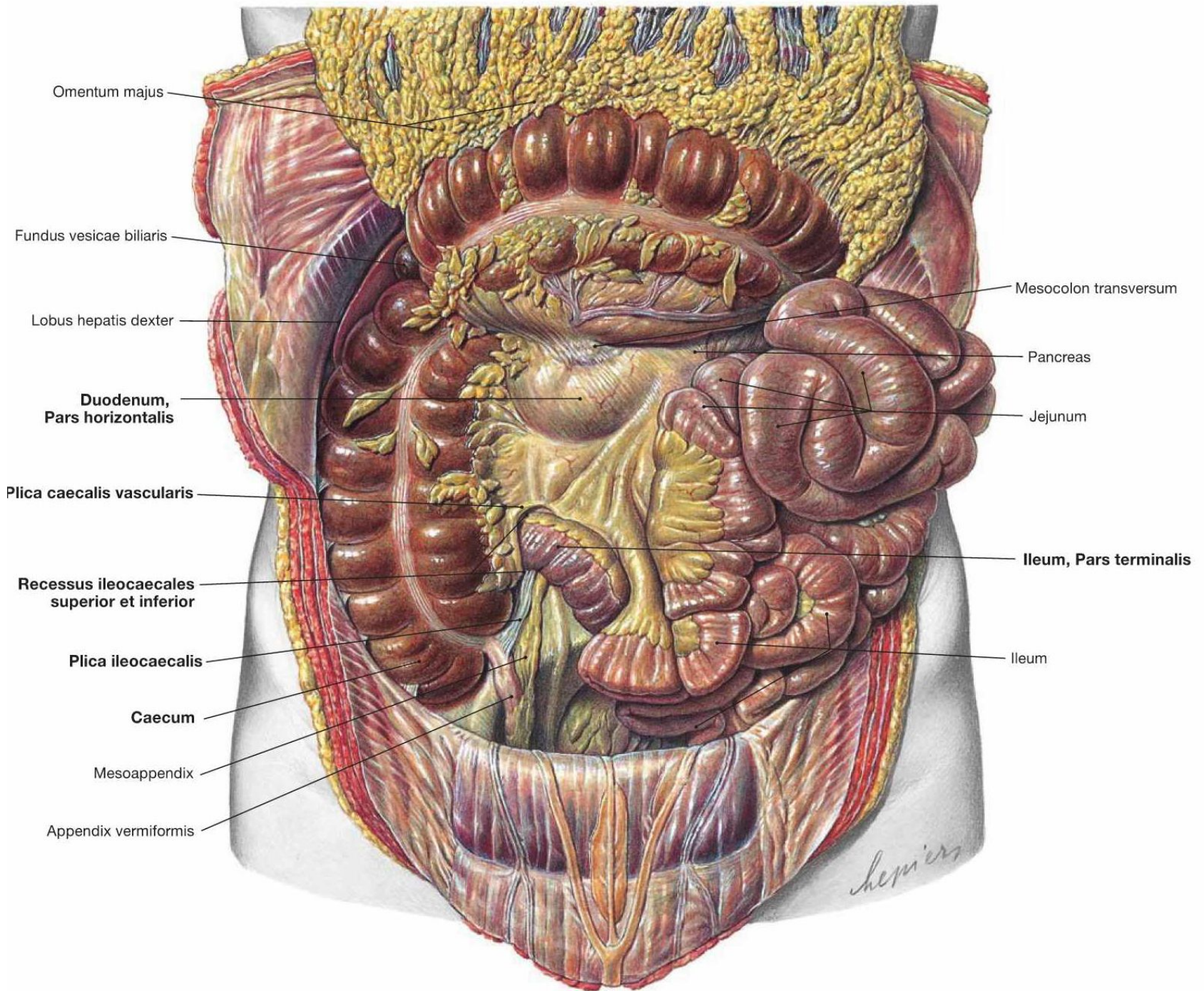
- excavatio rectovesicalis
- excavatio rectouterina – pouch of Douglas
- excavatio vesicouterina
  
- ligamentum falciforme hepatis
  - ligamentum teres hepatis
- plicae umbilicales
  - mediana, medialis, lateralis
- fossa supravesicalis, fossa inguinalis medialis et lateralis

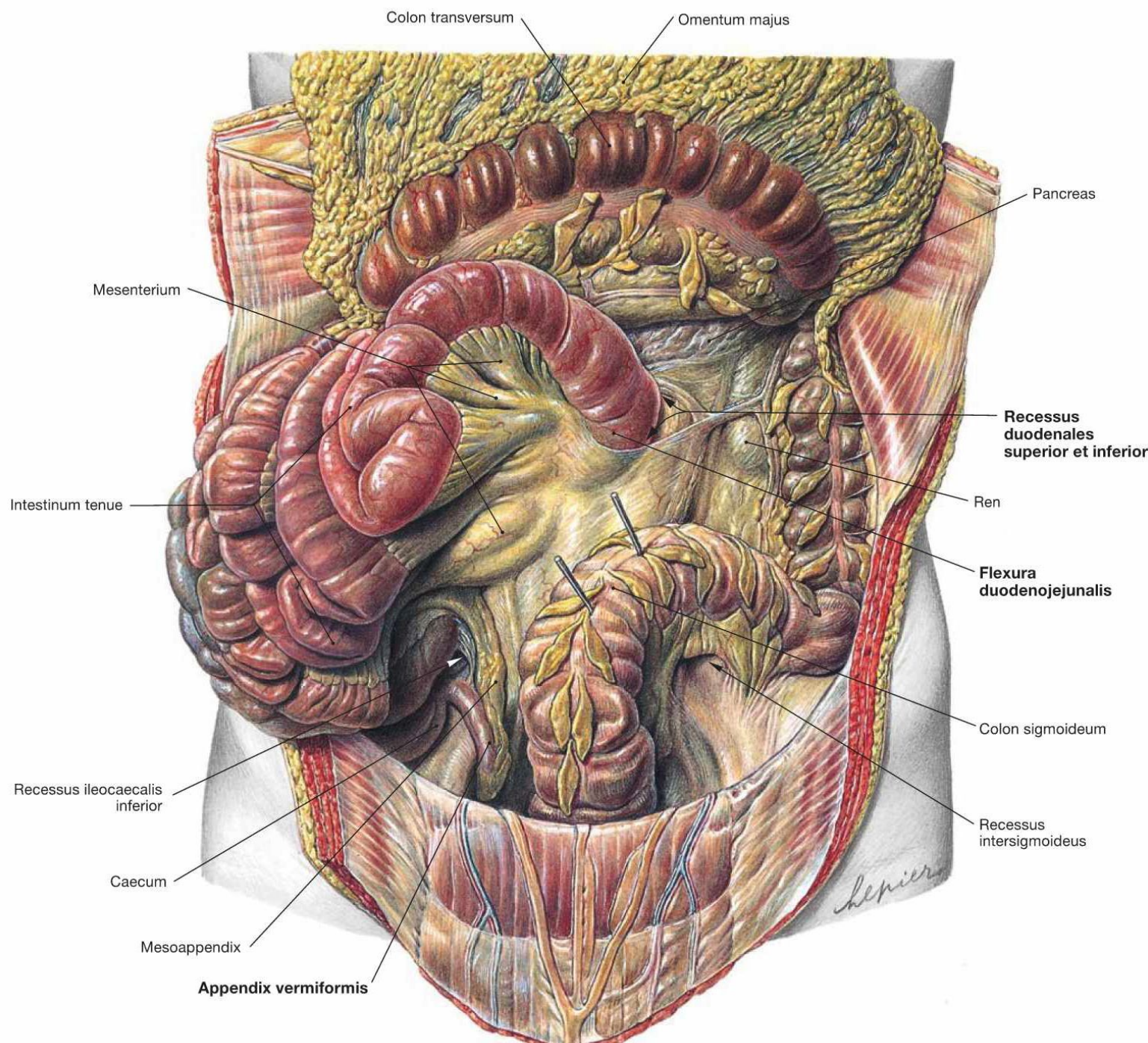


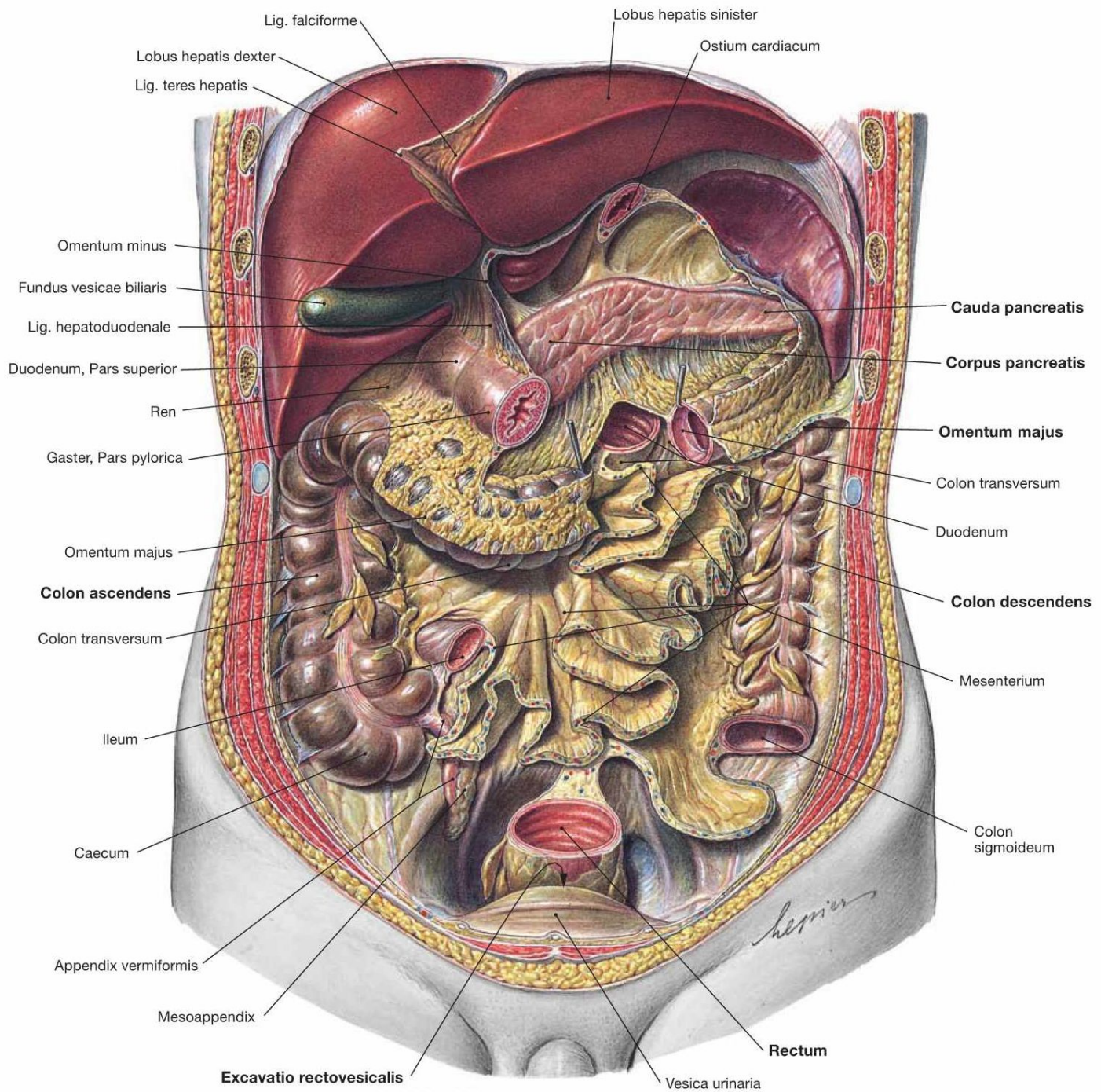












Lig. falciforme

Lobus hepatis sinister

Lobus hepatis dexter

Ostium cardiacum

Lig. teres hepatis

Omentum minus

Fundus vesicae biliaris

Lig. hepatoduodenale

Duodenum, Pars superior

Ren

Gaster, Pars pylorica

Cauda pancreatis

Corpus pancreatis

Omentum majus

Colon transversum

Duodenum

Omentum majus

Colon ascendens

Colon descendens

Colon transversum

Mesenterium

Ileum

Colon sigmoideum

Caecum

Appendix vermiformis

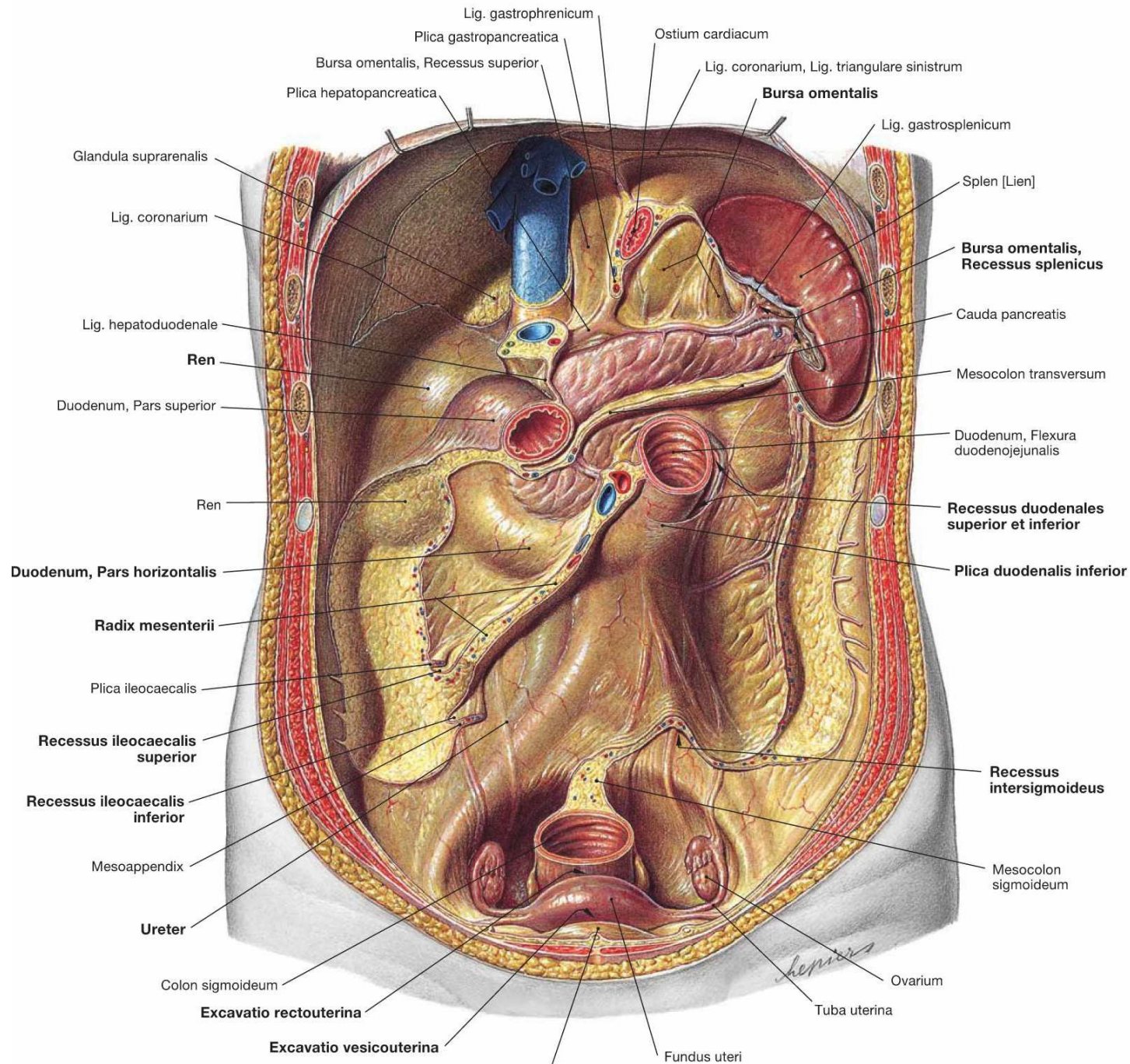
*Leprieux*

Mesoappendix

Rectum

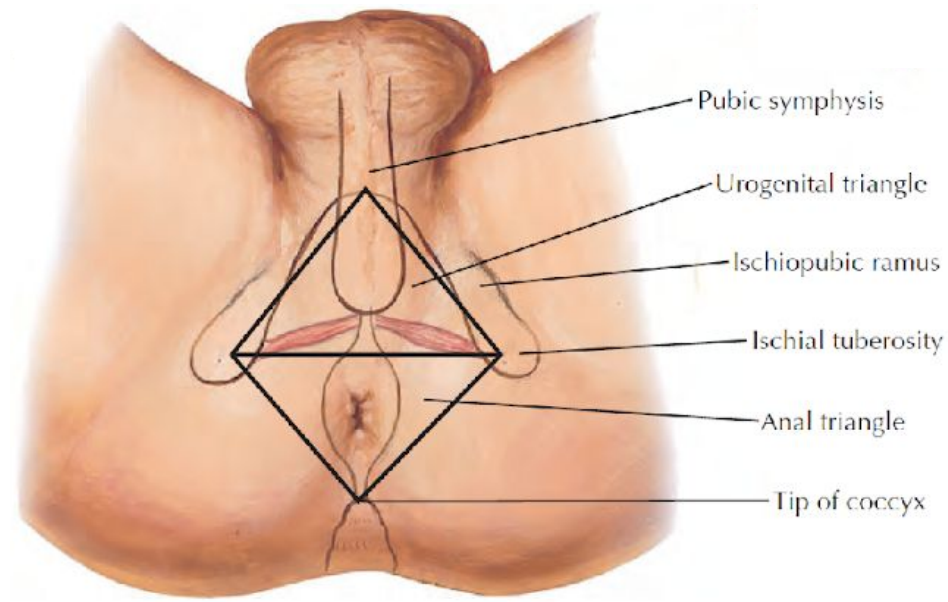
Excavatio rectovesicalis

Vesica urinaria



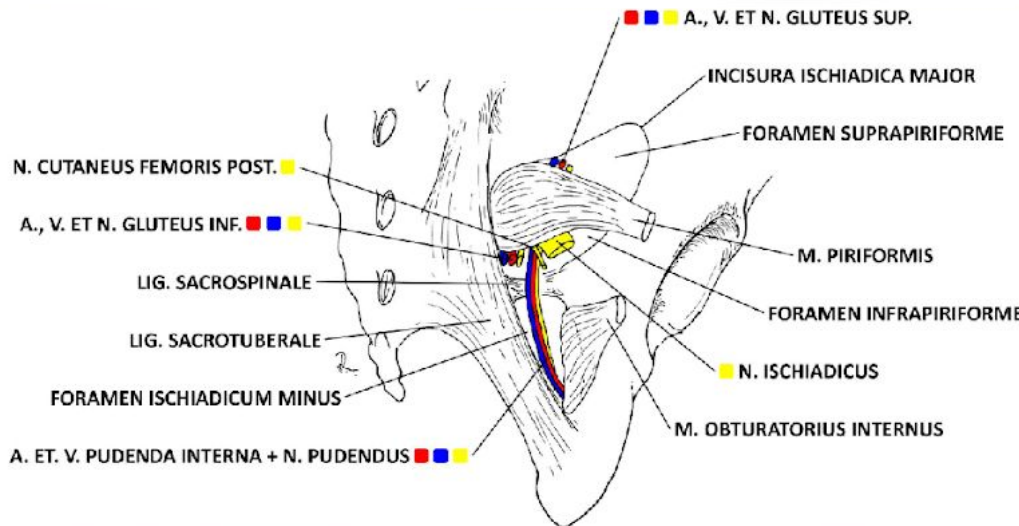
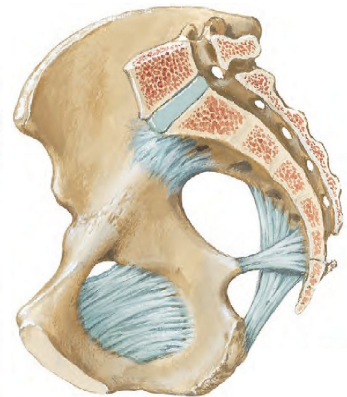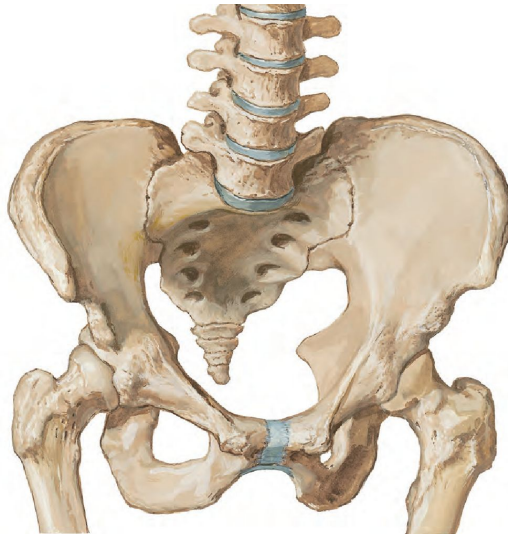
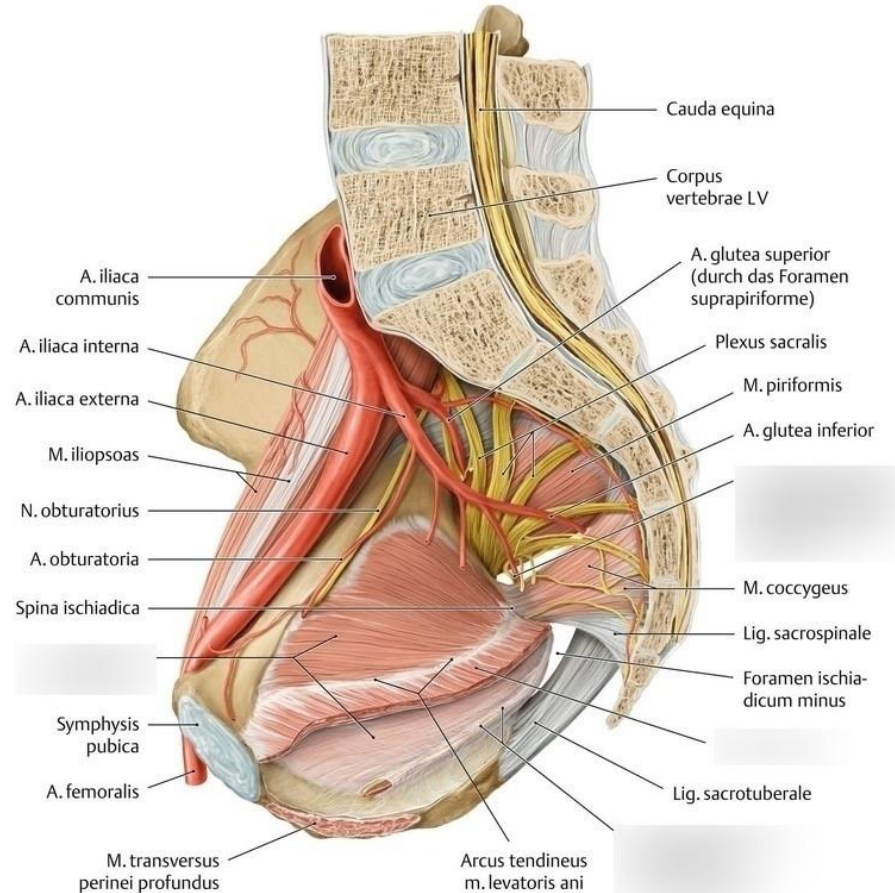
# Pelvic regions

- regio perinealis
  - regio analis s fossa ischioanalis
  - regio urogenitalis
  - perineum
- cavitas pelvis
  - pelvis major (peritoneal cavity)
  - pelvis minor



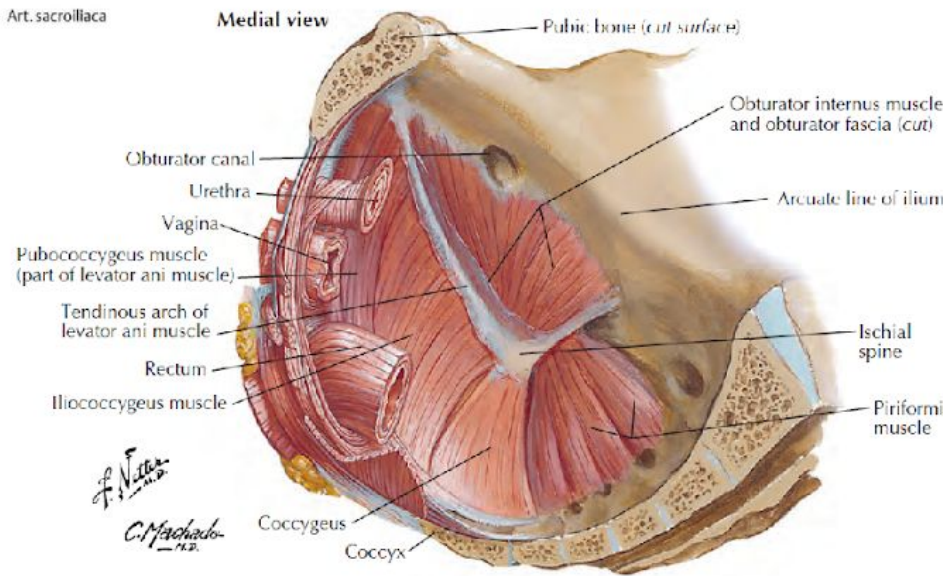
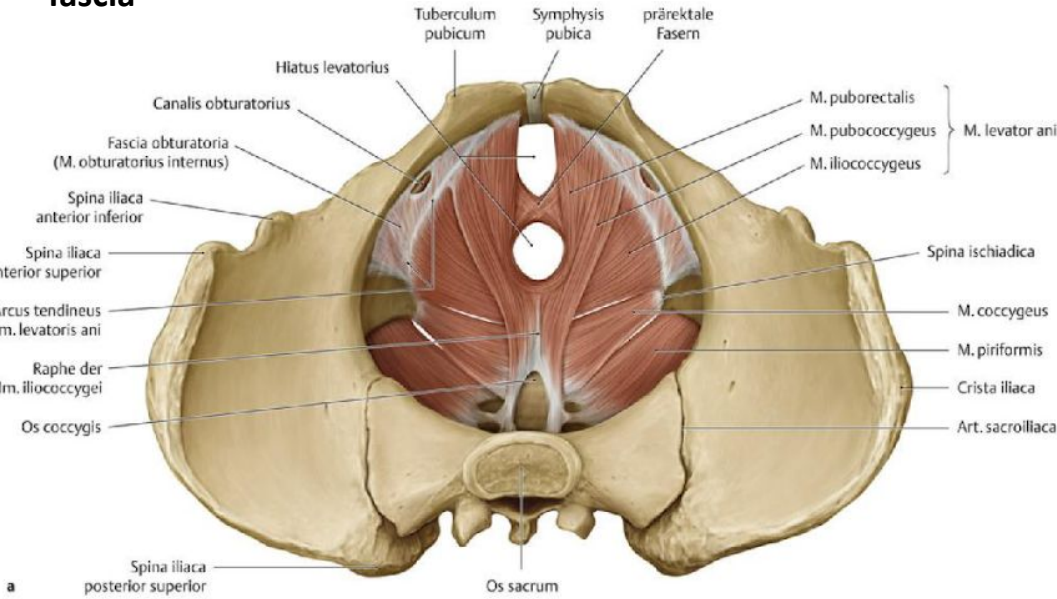
# Pelvis

- spojení ossa coxae a os sacrum – přenos váhy horní poloviny těla na dolní končetiny
- velká a malá (porodnická) pánev
  - hranice = linea terminalis (horní strana symfýzy, pecten ossis pubis, linea arcuata, promontorium)



# DIAPHRAGMA PELVIS

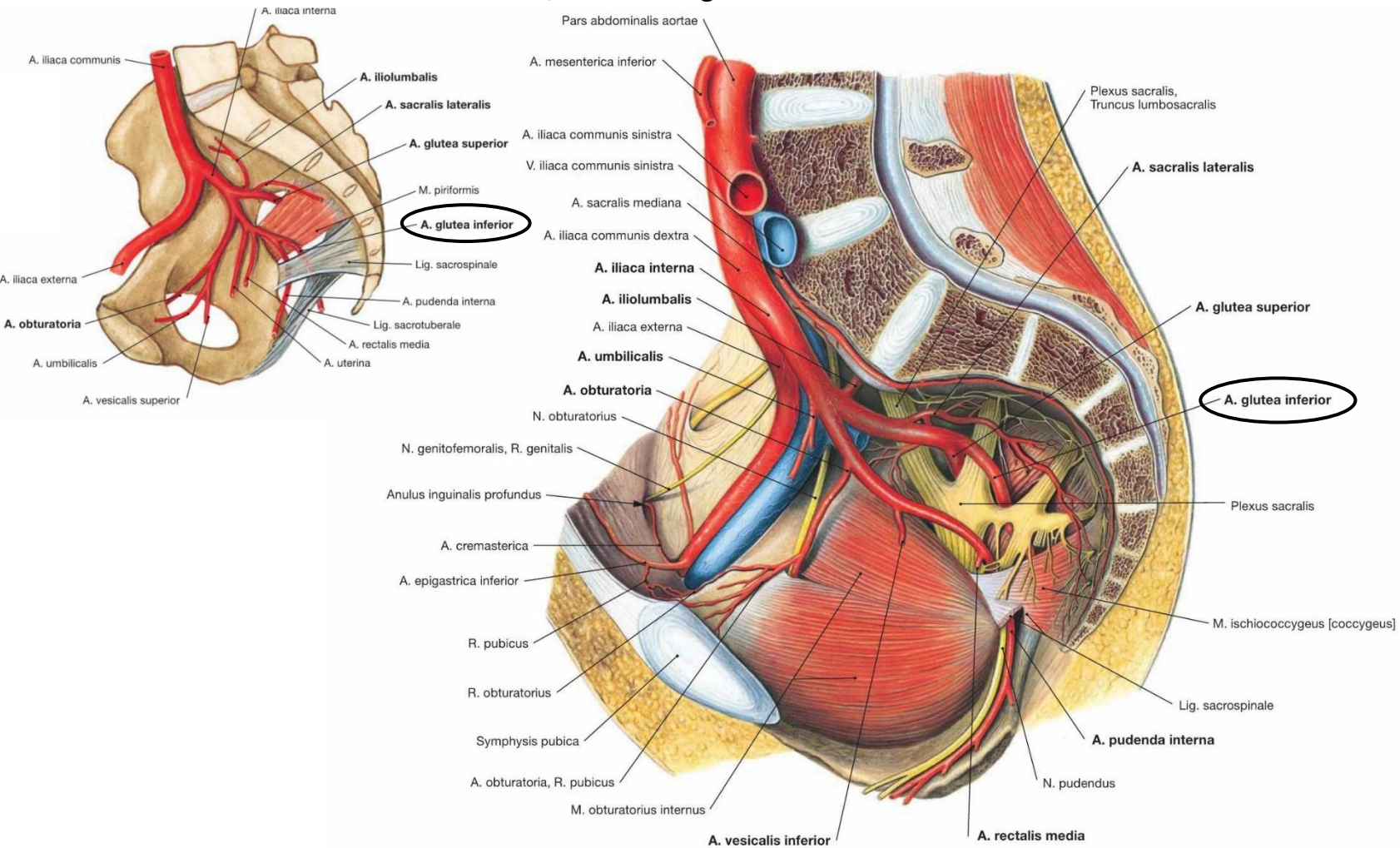
- m. levator ani
  - m. puborectalis
  - m. pubococcygeus
  - m iliococcygeus starts from the arcus tendinis musculi levatoris ani
- m. (ischio)coccygeus
- **parietal layer of the fascia pelvis** lies over the muscles
- connective tissue containing blood vessels and nerves that extends toward the organs is the **visceral layer of the fascia**



# PELVIC ARTERIES

- common iliac artery

- originates from the bifurcation of the aorta at the level of L4, angle between the right and left arteries 70°
- run laterocaudally along the medial edge of the psoas major muscle, at the level of the sacroiliac joint they divide into
- a. iliaca interna – into the small pelvis, dividing into ventral and dorsal trunks
- a. iliaca externa – along the m. psoas major to the lower limb
- in front of the aa. iliacae, the ureters (left vs. right)
- in front of the a. iliaca communis, the mesosigmoid attachment



# BRANCHES OF THE EXTERNAL ILIAC ARTERY

- under the parietal peritoneum at the medial edge of the psoas major muscle
  - medially to the external iliac vein, crossed on the right by the ureter and appendix (in pelvic position), on the left by the mesocolon sigmoideum, bilaterally across the ovarian artery
  - into the lacuna vasorum – femoral artery
  - supplies the lower part of the anterior abdominal wall and the wall of the greater pelvis
- 
- **inferior epigastric artery**
    - along the posterior wall of the inguinal canal, cranially and medially under the peritoneum into the vagina of the rectus abdominis muscle
    - at the level of the navel, anastomosing with branches of the superior epigastric artery.
    - pubic artery – then the obturator artery, anastomosing with the obturator artery (corona mortis)
  - **deep circumflex iliac artery**
    - at the inguinal ligament
    - iliacus muscle, abdominal wall muscles

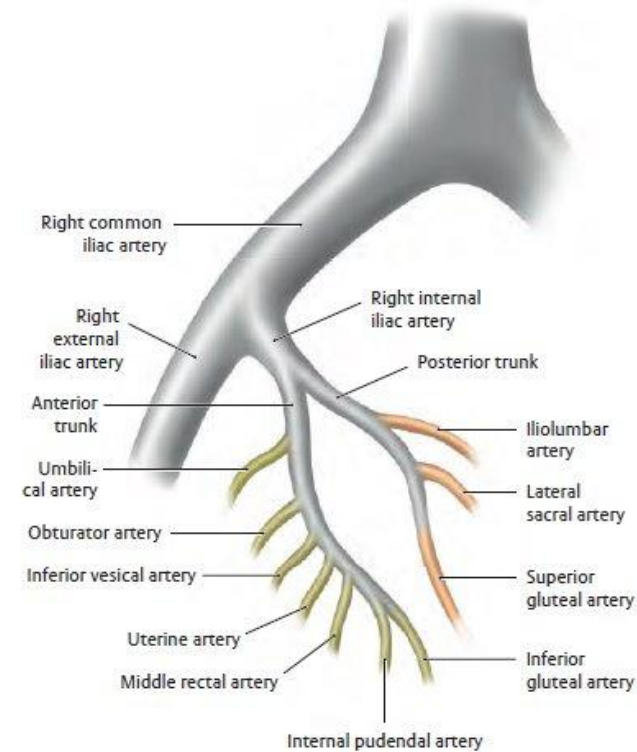
# BRANCHES OF THE INTERNAL ILIAC ARTERY I.

## dorsal trunk

- iliolumbal artery
  - posteriorly and cranially (under m. psoas major)
  - m. iliacus (r. iliacus), m. psoas and m. quadratus lumborum (r. lumbalis)
- lateral sacral artery
  - on the ventral surface of the sacrum
  - spinal canal, dorsal muscles
- superior gluteal artery
  - continuation of the dorsal trunk, into the suprapiriform foramen
  - mm. glutei

## ventral trunk – parietal branches

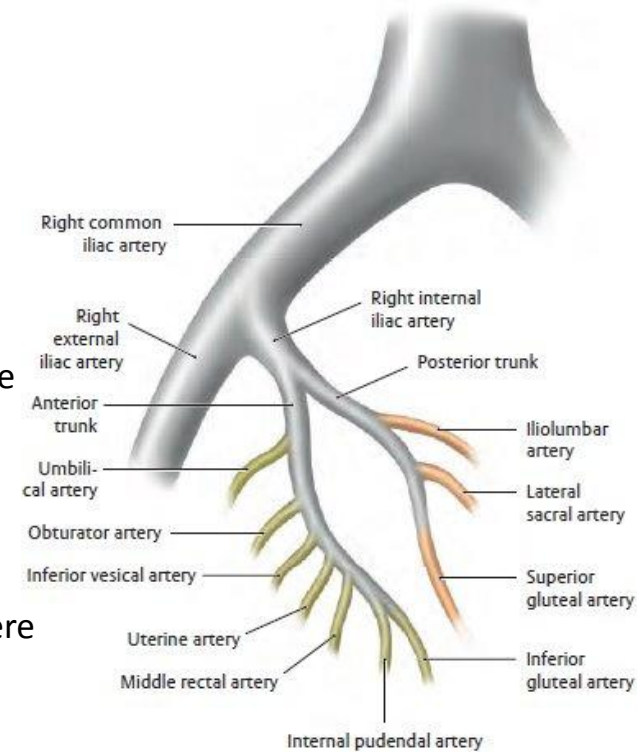
- obturator artery
  - after m. obturatorius internus, before entering canalis obturatorius gives branch r. pubicus (anast. with r. pubicus from a. epigastrica inf., corona mortis), after exit r. anterior (adductors of thigh), r. posterior (pelvitrochanteric muscles, hip joint)
- inferior gluteal artery
  - between the roots of the sacral plexus into the infrapiriform foramen
  - mm. glutei



# BRANCHES OF THE INTERNAL ILIAC ARTERY II.

## ventral trunk – visceral branches

- **a. vesicalis superior**
  - remnant of a. umbilicalis (proximal patent pars patens)
  - upper part of the urinary bladder
- **a. vesicalis inferior**
  - bottom of the urinary bladder, prostate and seminal vesicles/fornix vaginae
- **a. rectalis media**
  - distal part of the rectum, prostate, seminal vesicles, anastomosis with a. rectalis inferior
- **a. uterina**
  - in women to the edge of the uterus at the base of the lig. latum uteri (where it crosses under the ureter), then divides
  - ascending branch – tubal branch, ovarian branch; anastomoses with the ovarian artery
  - descending branch – ends as the vaginal artery
- **ductus deferens artery**
  - in men, ascending branch and descending branch (in the spermatic cord to the scrotum)
- **internal pudendal artery**
  - through the infrapiriform foramen, wraps around the ischial spine from behind, returns through the lesser sciatic foramen to the small pelvis
  - in Alcock's canal to the perineum
  - pars analis recti, pelvic floor, perineum, penis/clitoris (continuation of the trunk of the a. penis/a. clitoridis)
  - a. rectalis inferior – anastomosis with a. rectalis media
  - a. perinealis

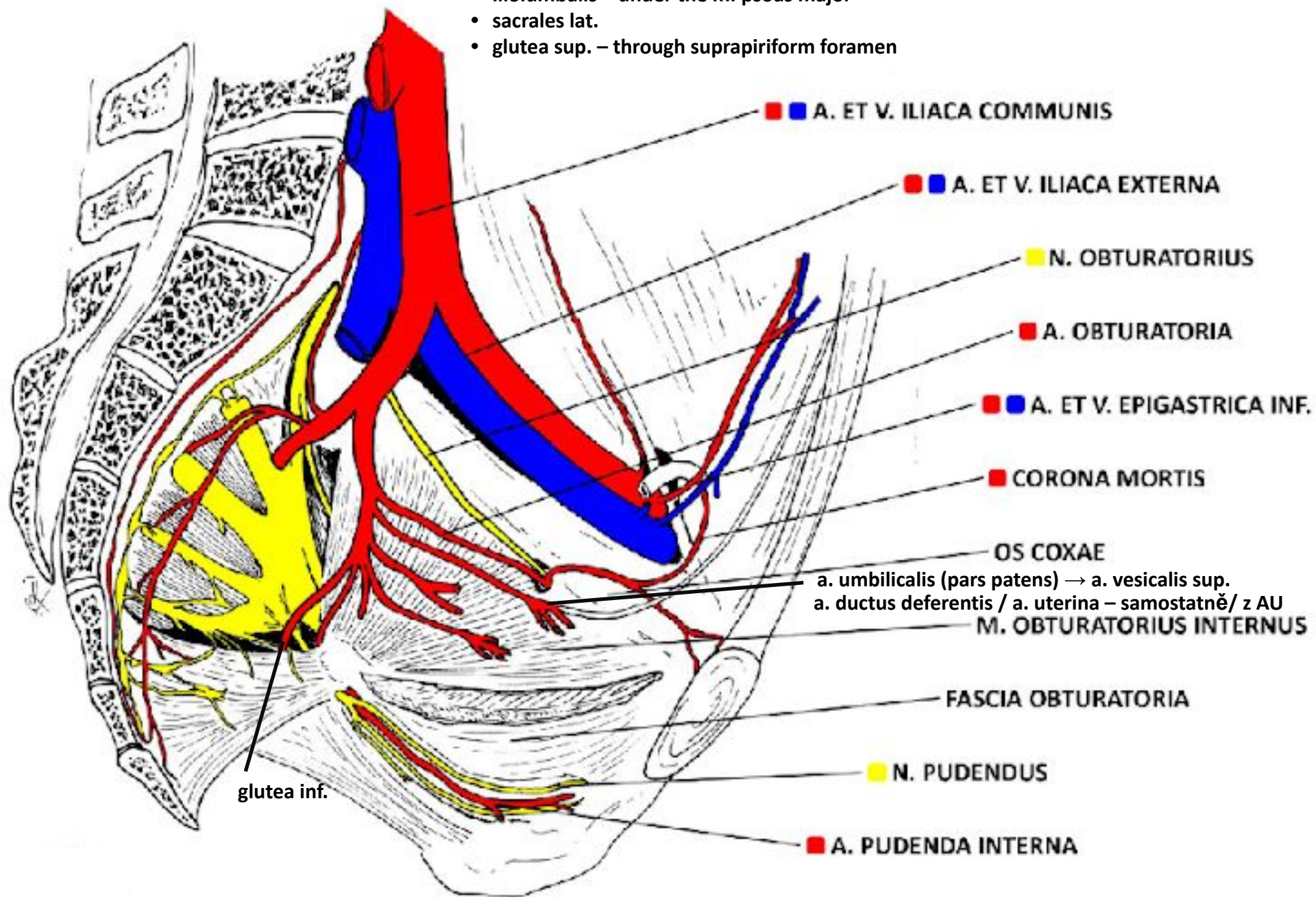


# A. ILIACA INTERNA

dorsal trunk

ventral trunk

- iliolumbalis – under the m. psoas major
- sacrales lat.
- glutea sup. – through suprapiriform foramen



■ ■ A. ET V. ILIACA COMMUNIS

■ ■ A. ET V. ILIACA EXTERNA

■ N. OBTURATORIUS

■ A. OBTURATORIA

■ ■ A. ET V. EPIGASTRICA INF.

■ CORONA MORTIS

OS COXAE

a. umbilicalis (pars patens) → a. vesicalis sup.  
 a. ductus deferentis / a. uterina – samostatně / z AU

M. OBTURATORIUS INTERNUS

FASCIA OBTURATORIA

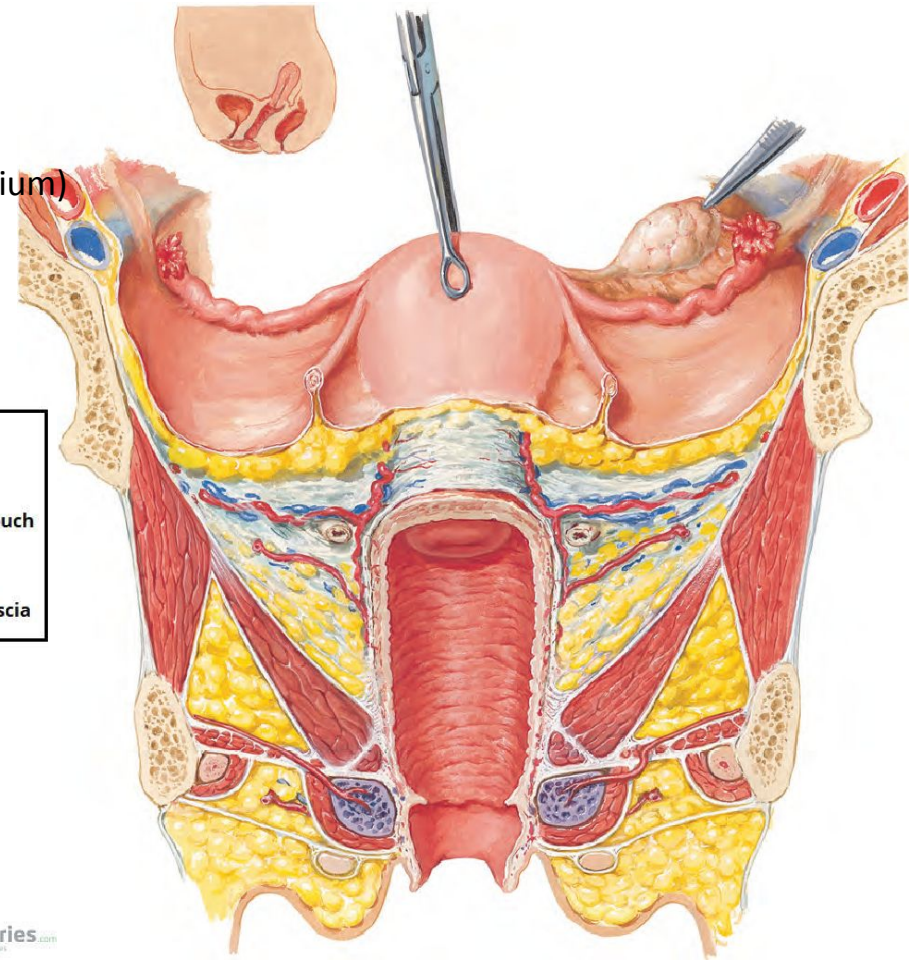
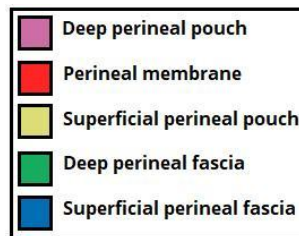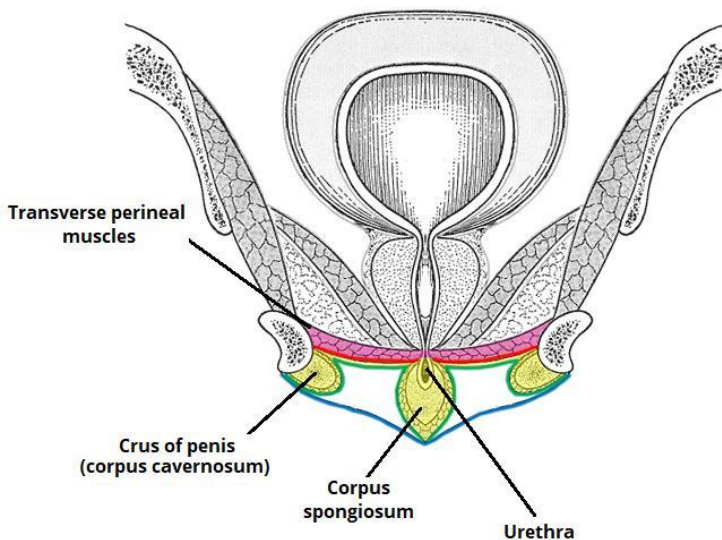
■ N. PUDENDUS

■ A. PUDENDA INTERNA

glutea inf.

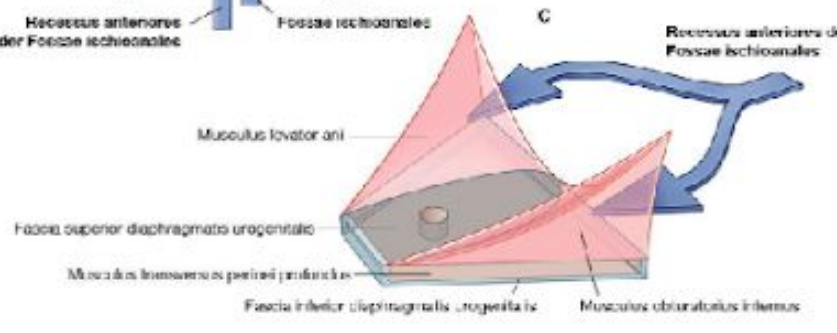
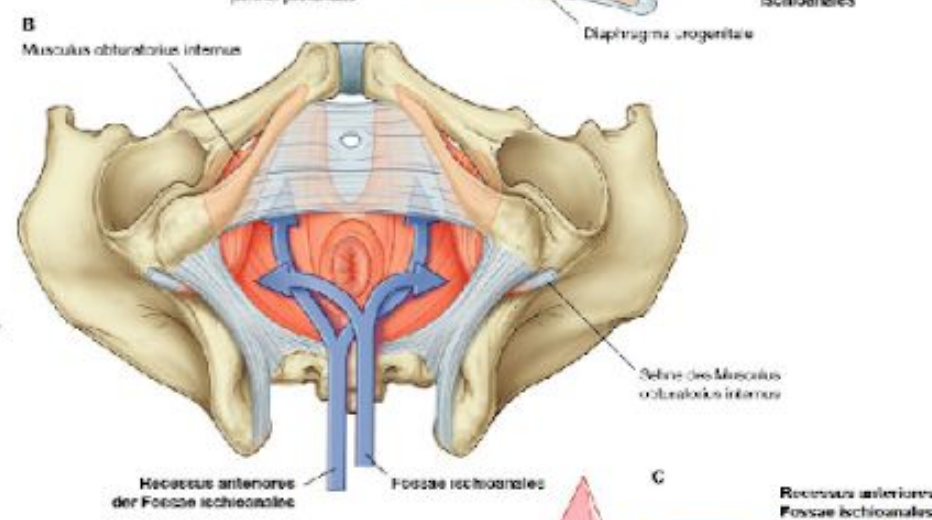
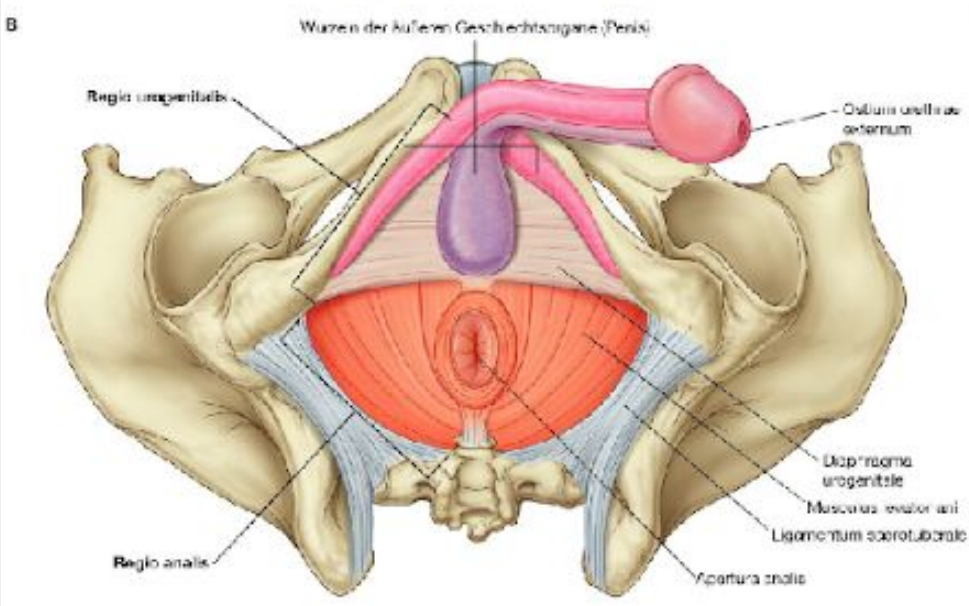
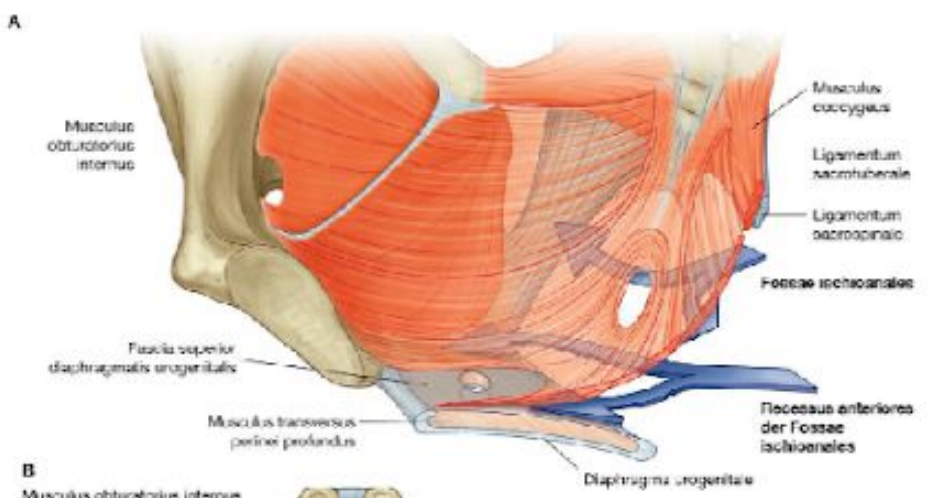
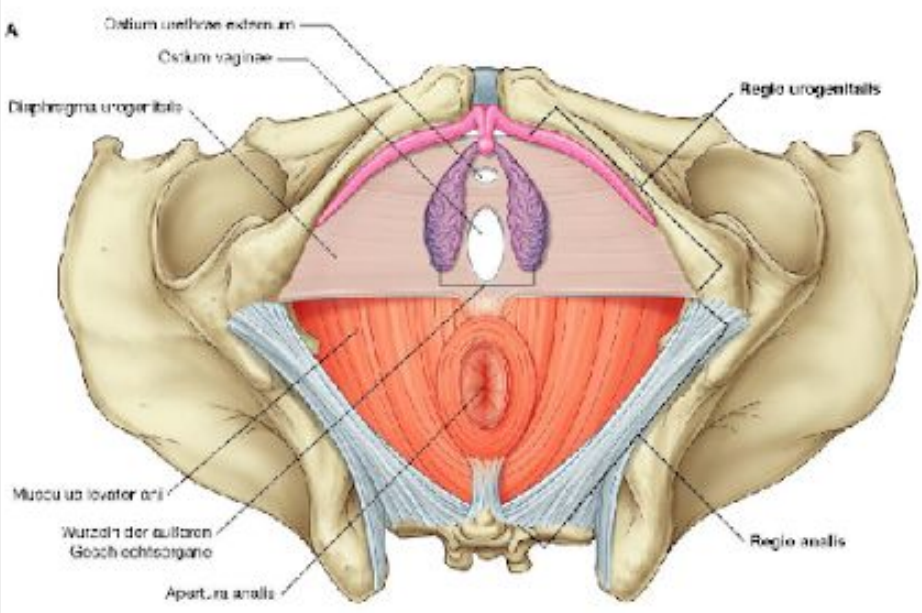
# REGIO UROGENITALIS

- Differences in anatomy between women and men
- Common layers
  - Skin
  - Superficial fat layer
  - Colles' fascia
  - Spatium perinei spf.
  - Gallaudet's fascia
  - Deep perineal space (muscles with erectile bodies, urethral muscles) with the perineal membrane
  - Fossa ischioanal (anteriorly, the pubic recess)
  - inferior pelvic diaphragmatic fascia
  - pelvic floor muscles
  - superior pelvic diaphragmatic fascia + obturator fascia
  - subperitoneal connective tissue (parametrium, paracolpium)
  - peritoneum



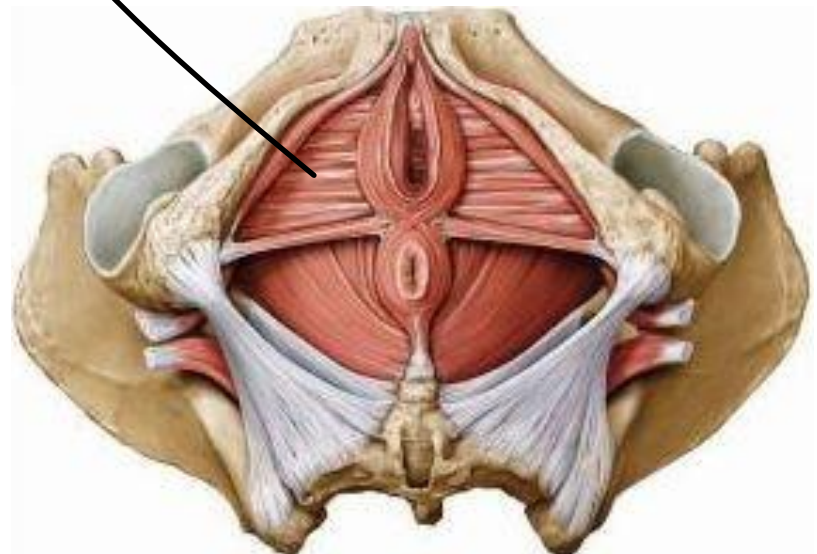
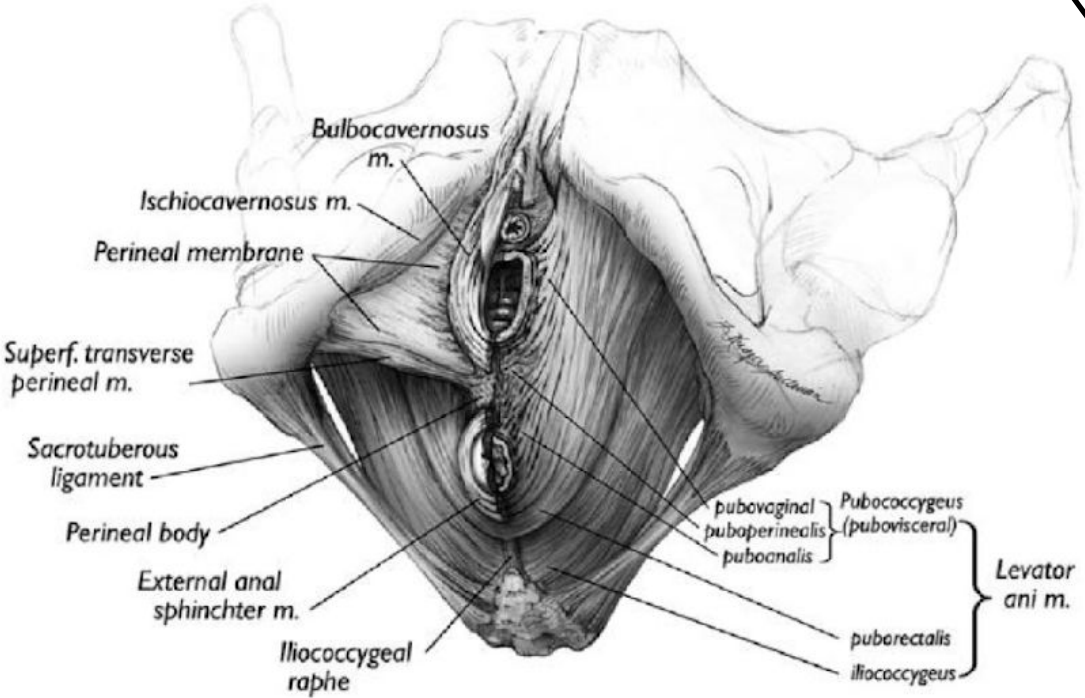
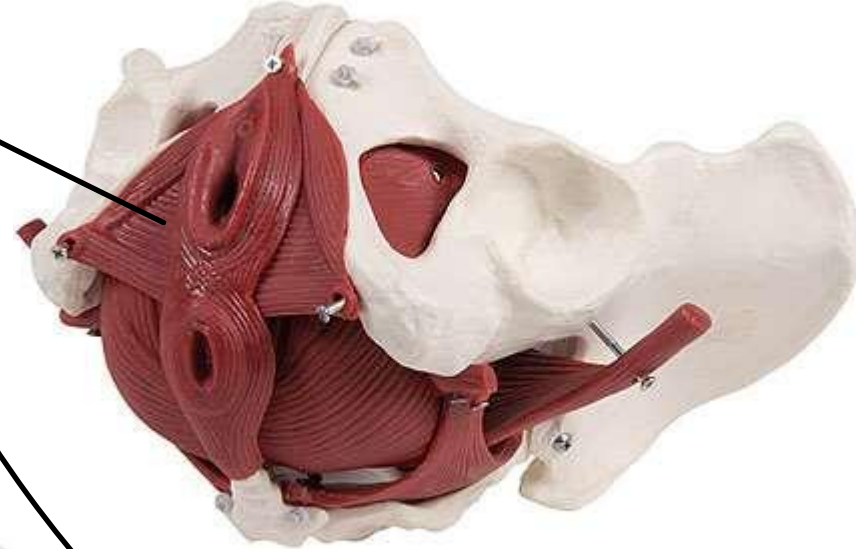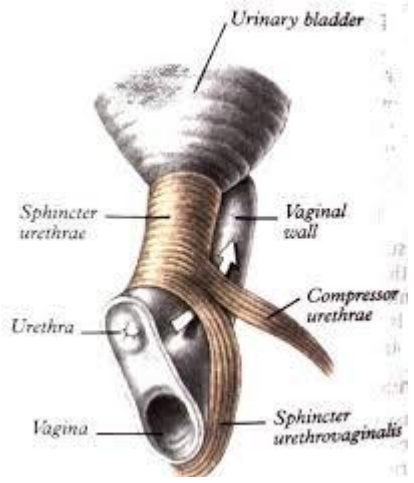
# REGIO UROGENITALIS

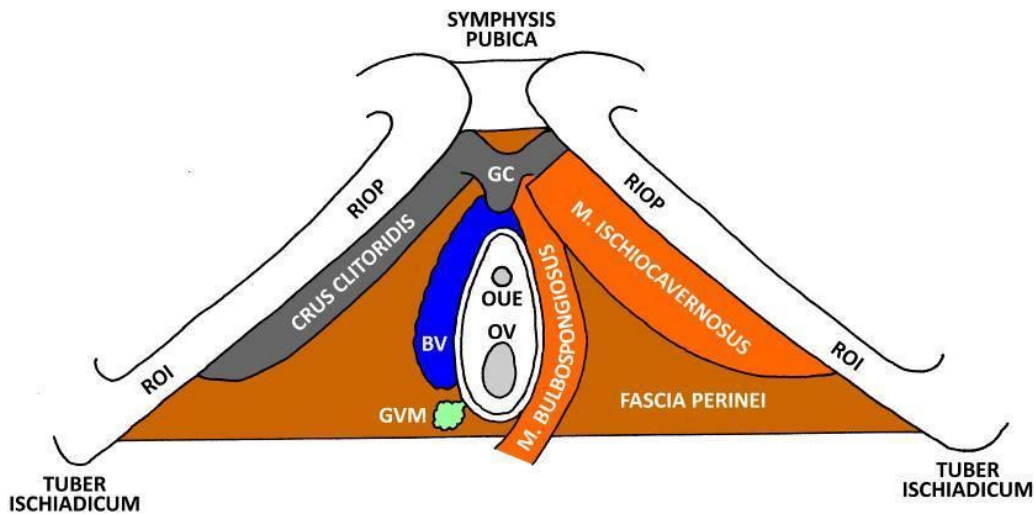
- female (A) and male (B)



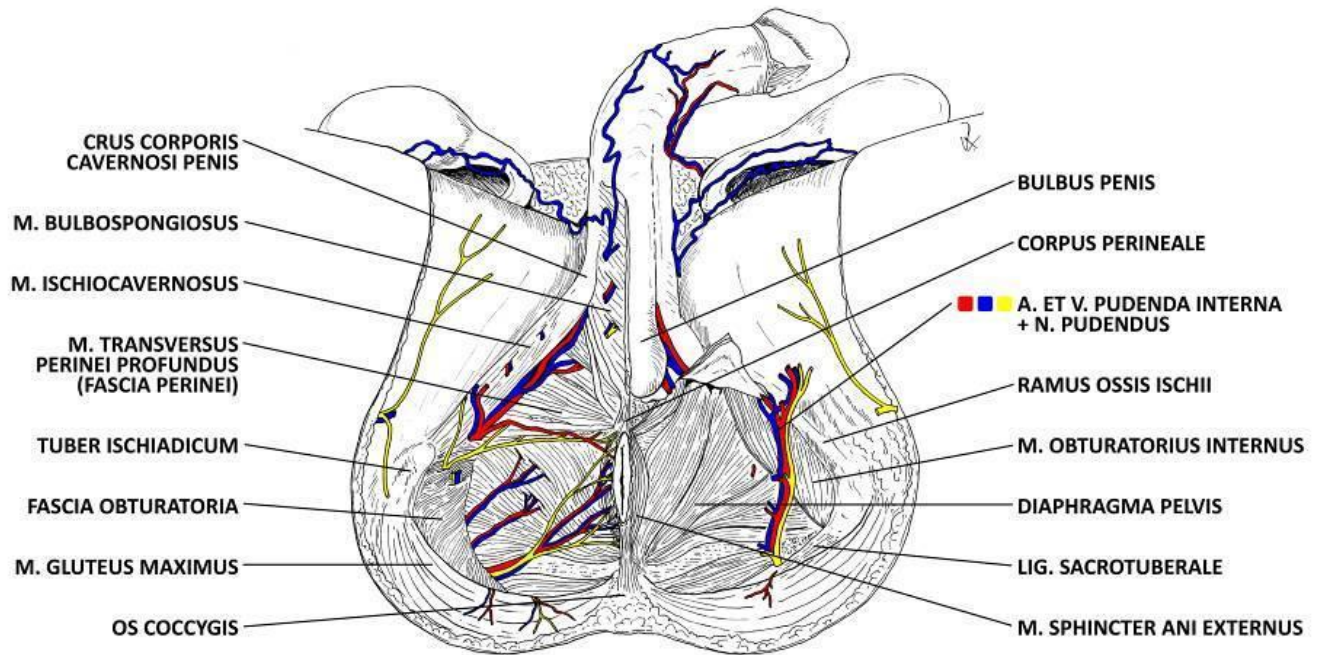
# REGIO UROGENITALIS FEMININA

The deep transverse perineal muscle is not present; a mixture of muscle fibers and connective tissue





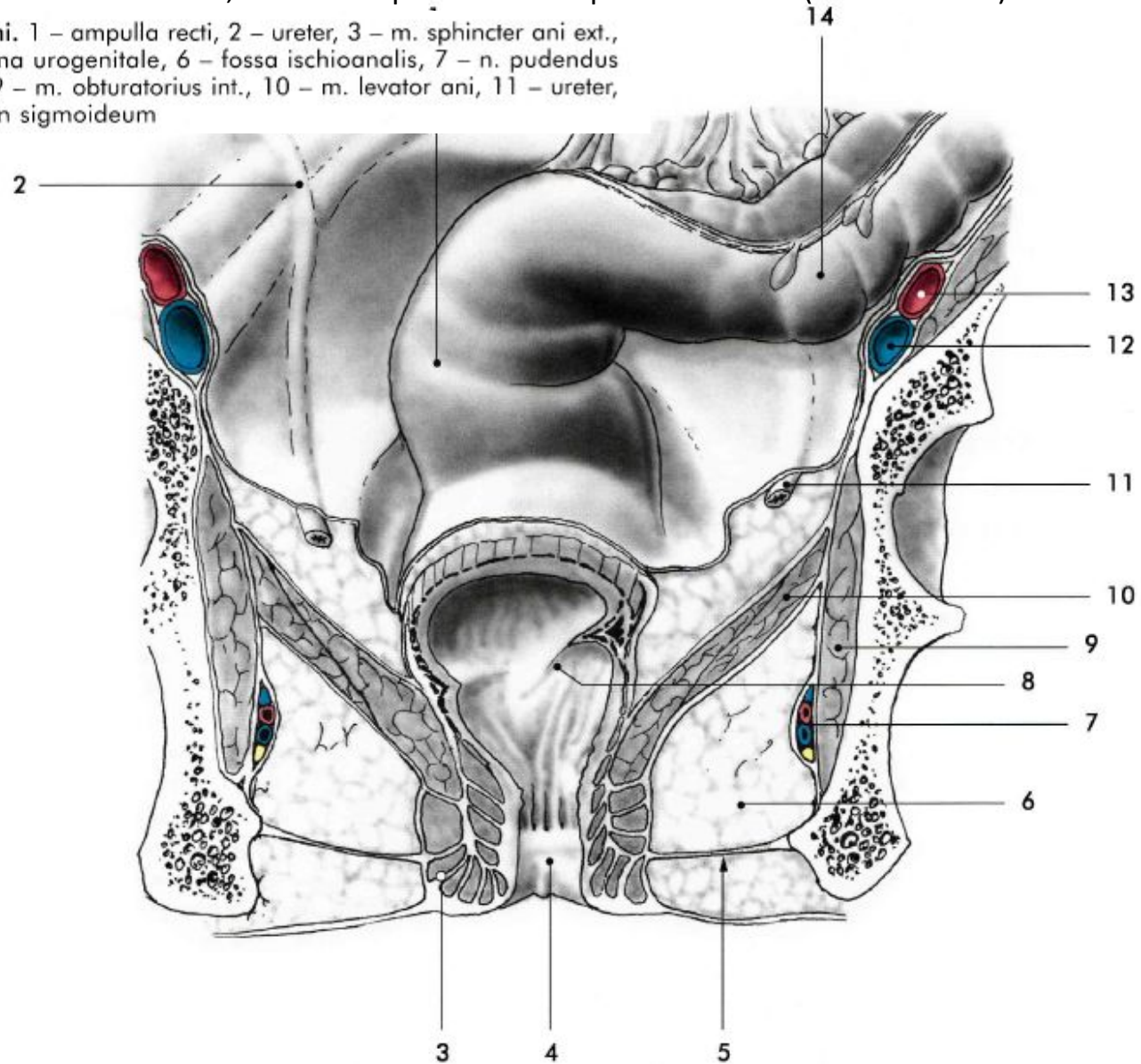
RIOP - R. INF. OSSIS PUBIS  
 ROI - R. OSSIS ISCHII  
 GC - GLANS CLITORIDIS  
 BV - BULBUS VESTIBULI  
 OUE - OSTIUM URETHRAE EXTERNUM  
 OV - ORIFICIUM VAGINAE  
 GVM - GLANDULA VESTIBULARIS MAJOR



# FOSSA ISCHIOANALIS

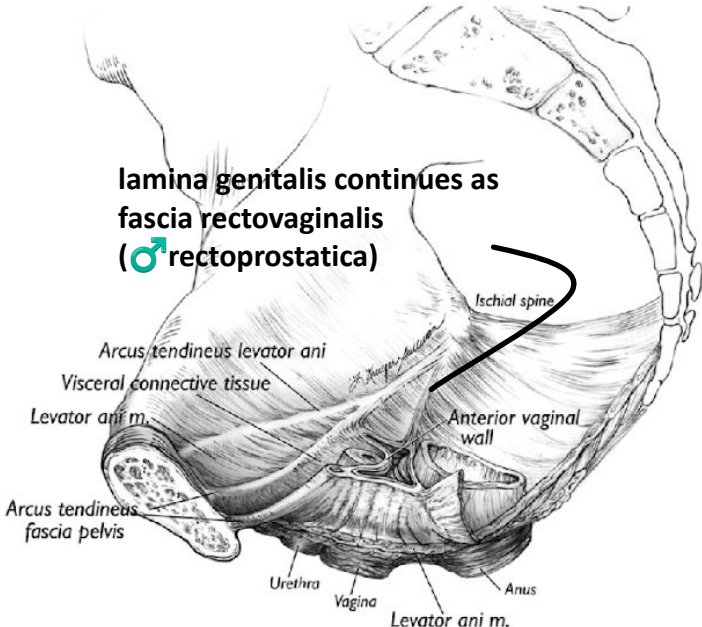
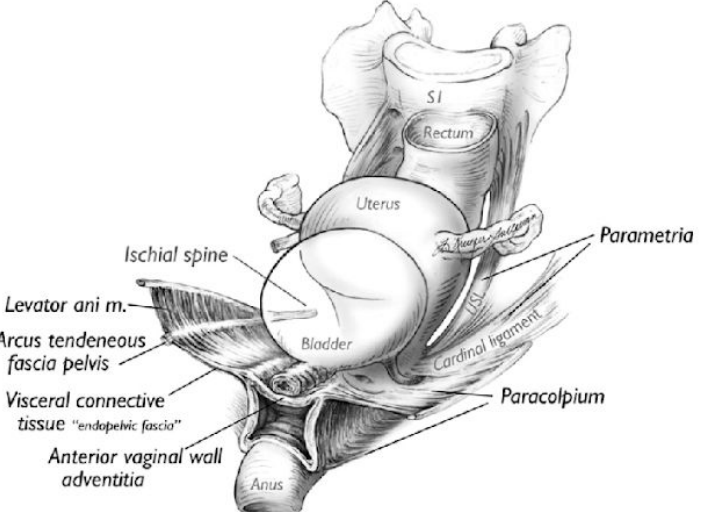
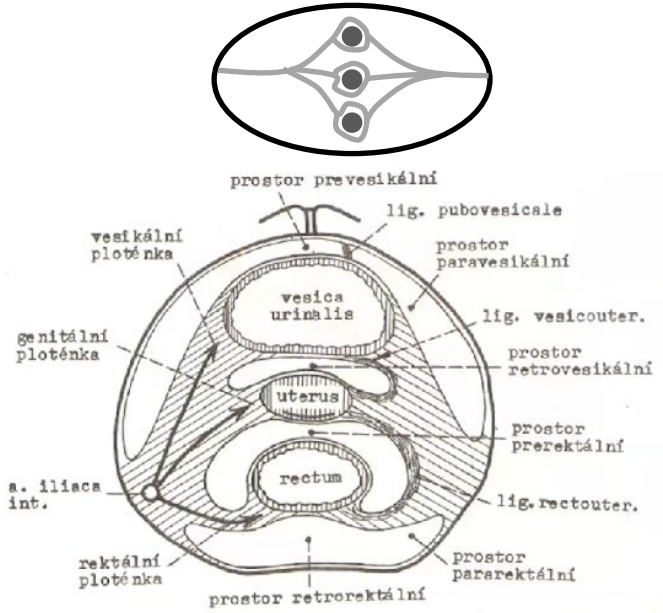
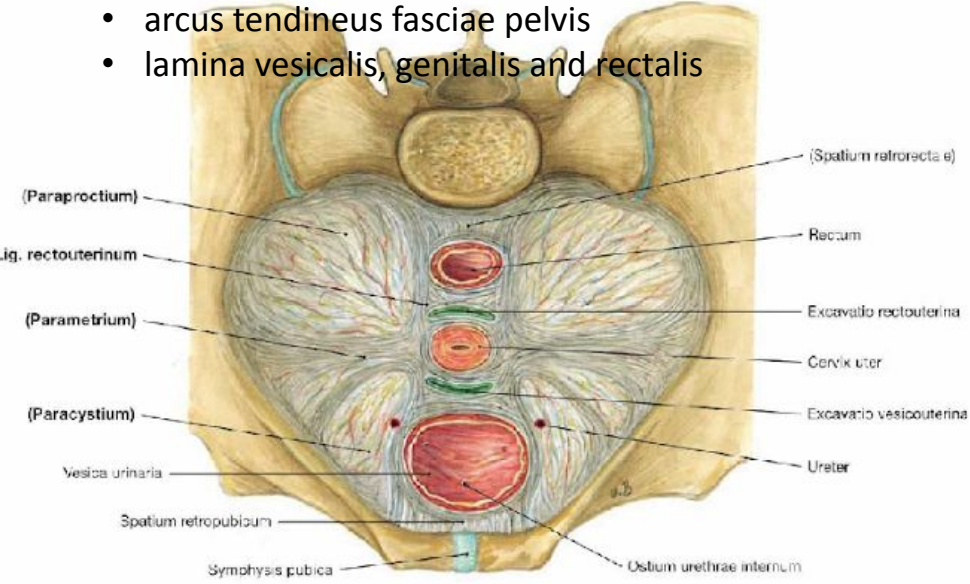
- filled with adipose tissue
- extends anteriorly to the symphysis pubis as the pubic recess
- on the inner surface of the internal obturator muscle, a fascial duplication—the pudendal canal (Alcock's canal)

Obr. 15.3.7. Frontální řez pánví v anální úrovni. 1 – ampulla recti, 2 – ureter, 3 – m. sphincter ani ext., 4 – canalis analis, 5 – dorzální okraj diaphragma urogenitale, 6 – fossa ischioanalis, 7 – n. pudendus et vasa pudenda int., 8 – plica transversa recti, 9 – m. obturatorius int., 10 – m. levator ani, 11 – ureter, 12 – v. iliaca ext., 13 – a. iliaca ext., 14 – colon sigmoideum

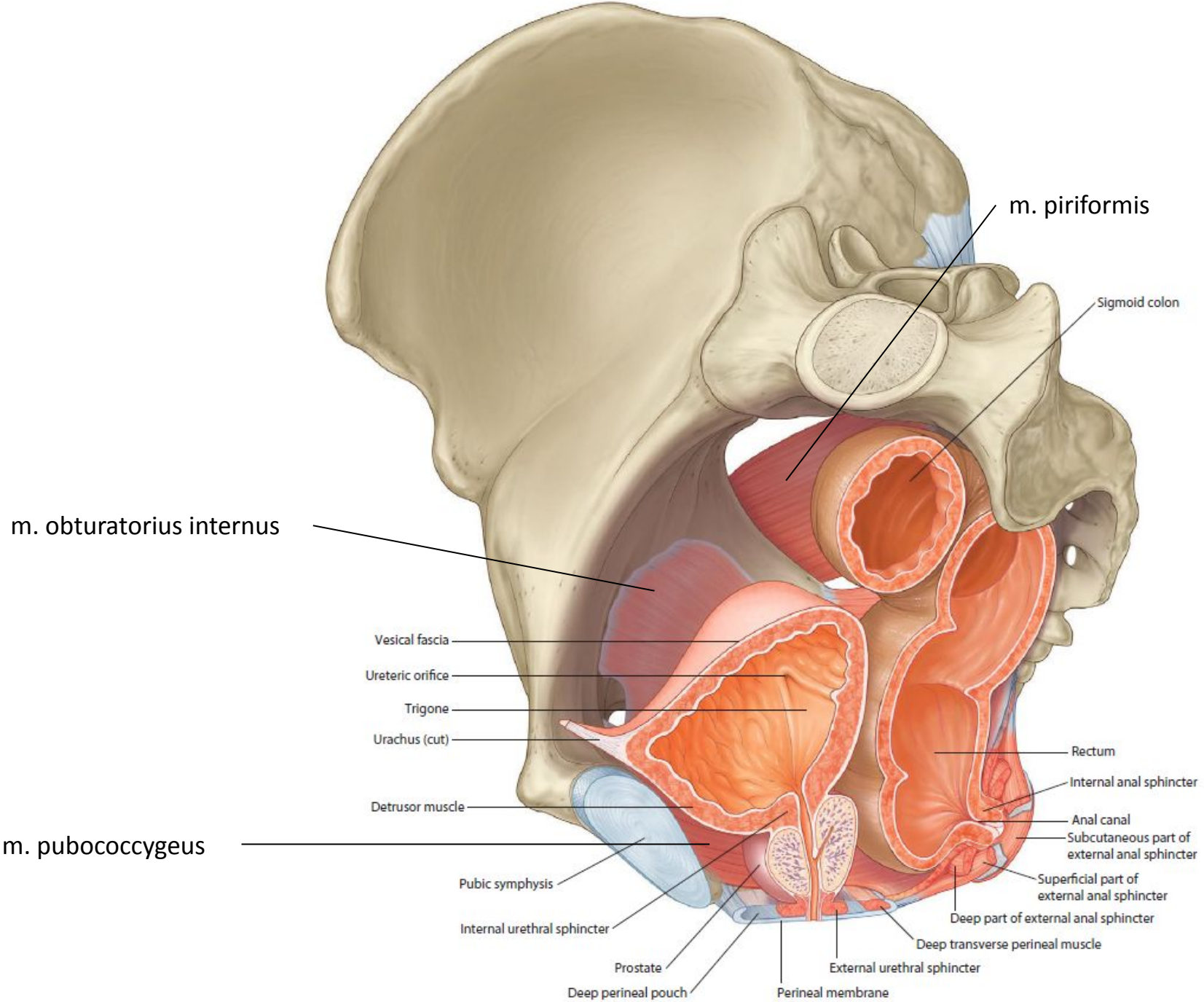


# FASCIAs and “ligaments” of the pelvic floor

- fascia pelvis parietalis (fascia endopelvica)
  - fascia obturatoria
  - fascia diaphragmatis pelvis superior
  - presacral fascia (no specific name, what a shame)
- fascia pelvis visceralis
  - arcus tendineus fasciae pelvis
  - lamina vesicalis, genitalis and rectalis



lamina genitalis continues as fascia rectovaginalis (♂rectoprostatica)



m. piriformis

Sigmoid colon

m. obturatorius internus

Vesical fascia

Ureteric orifice

Trigone

Urachus (cut)

Detrusor muscle

m. pubococcygeus

Pubic symphysis

Internal urethral sphincter

Prostate

Deep perineal pouch

Perineal membrane

External urethral sphincter

Deep transverse perineal muscle

Deep part of external anal sphincter

Superficial part of external anal sphincter

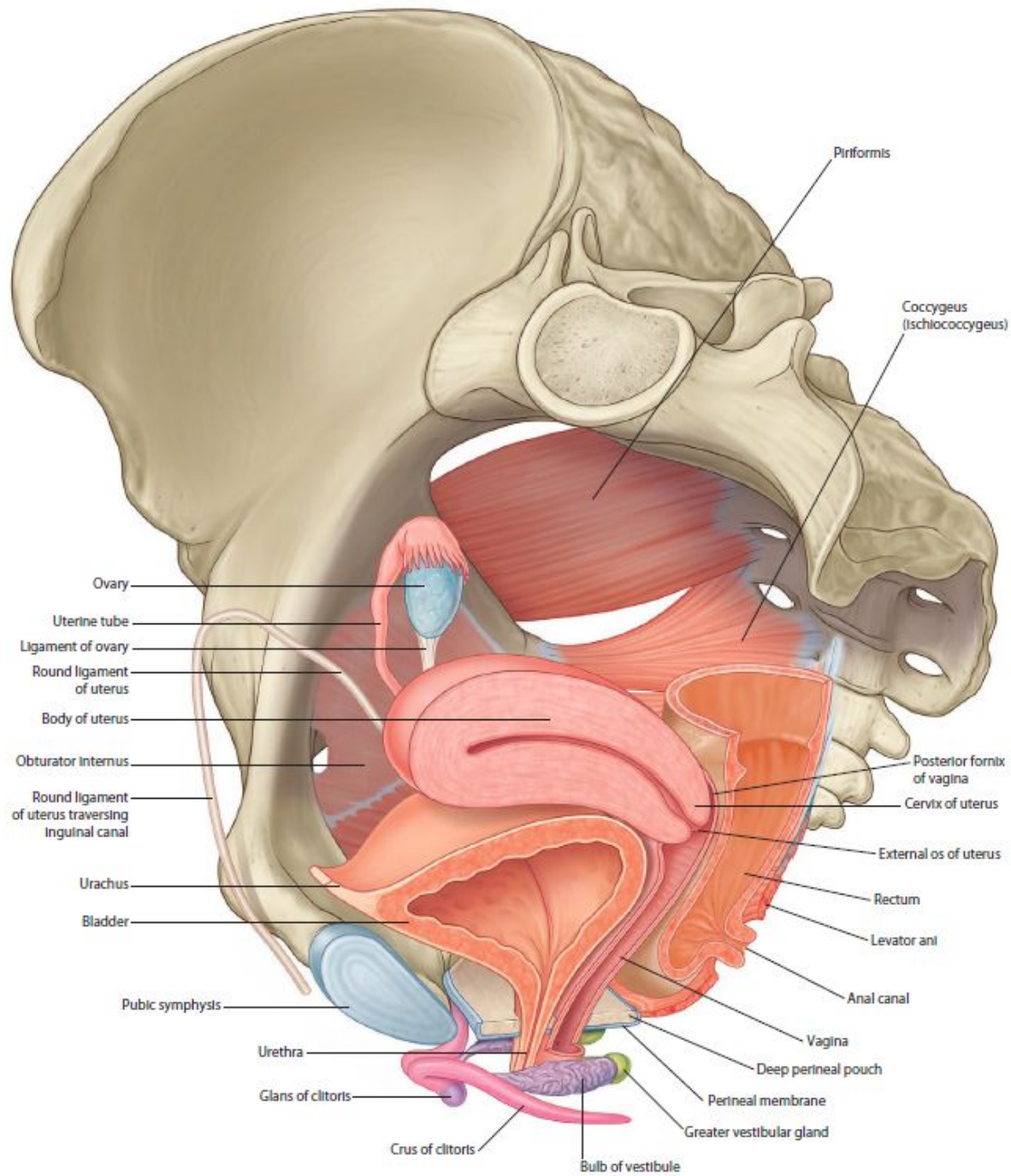
Subcutaneous part of external anal sphincter

Anal canal

Internal anal sphincter

Rectum

**Bladder, prostate, and rectum within pelvic cavity in men (oblique sagittal view)**



- Piriformis
- Coccygeus (Ischiococcygeus)
- Ovary
- Uterine tube
- Ligament of ovary
- Round ligament of uterus
- Body of uterus
- Obturator internus
- Round ligament of uterus traversing inguinal canal
- Urachus
- Bladder
- Pubic symphysis
- Urethra
- Glans of clitoris
- Crus of clitoris
- Bulb of vestibule
- Posterior fornix of vagina
- Cervix of uterus
- External os of uterus
- Rectum
- Levator ani
- Anal canal
- Vagina
- Deep perineal pouch
- Perineal membrane
- Greater vestibular gland

Reproductive system in women (oblique sagittal view)